

# Oral Histopathology

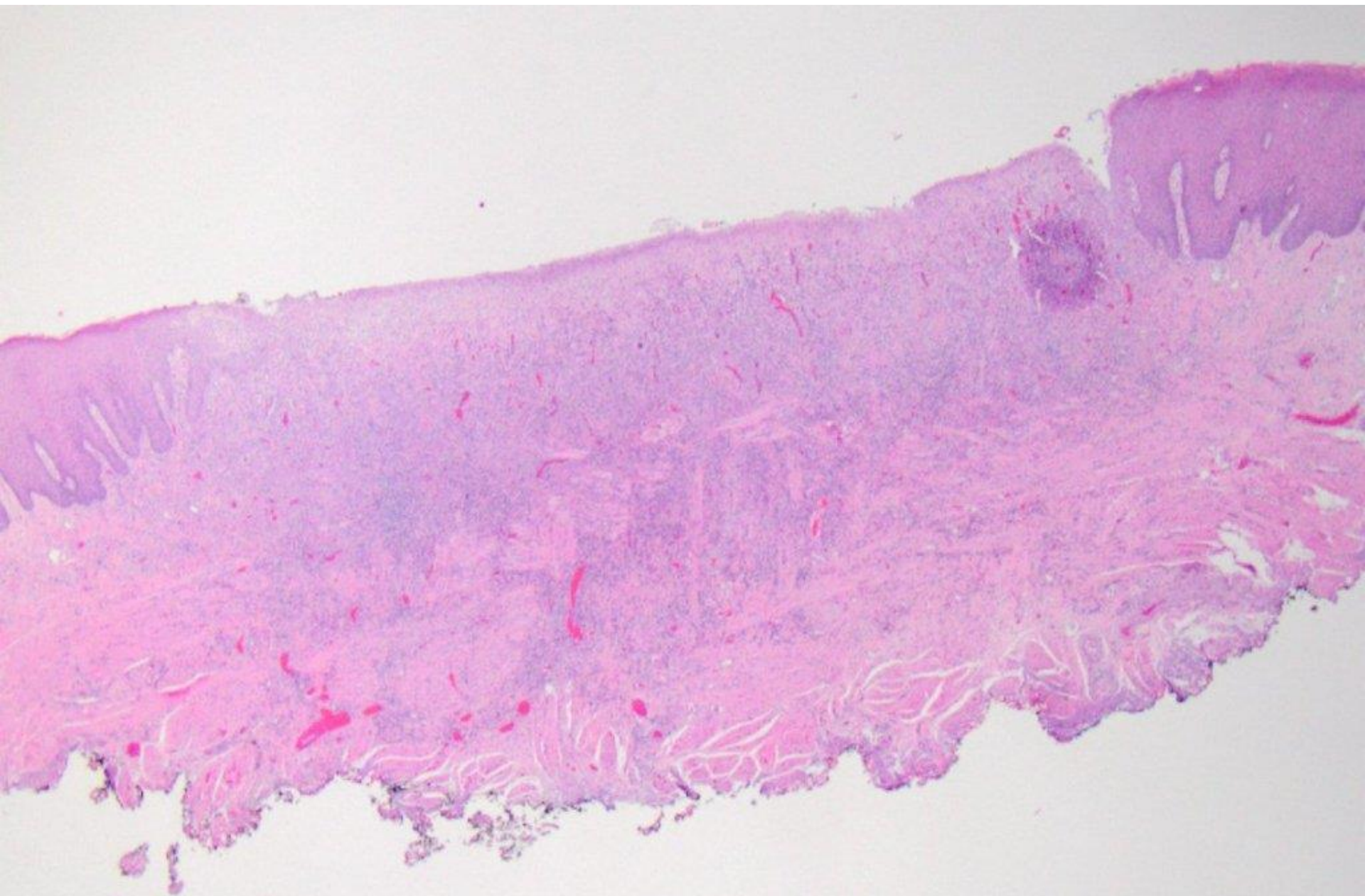
## Series 2 (abnormal histologic findings)

**DAVID E. KLINGMAN, DMD**

*Diplomate, American Board of Oral and Maxillofacial Pathology*

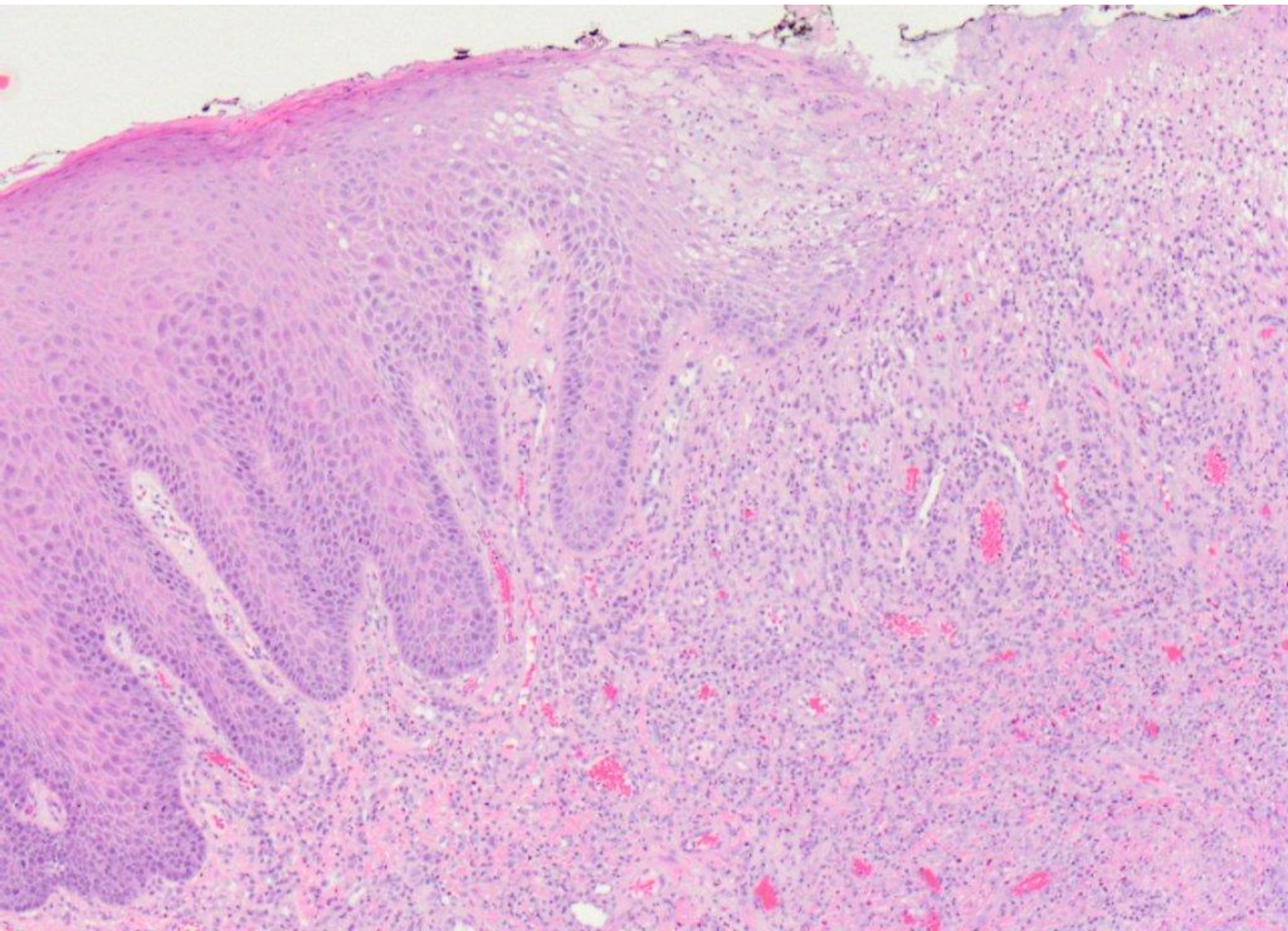
*Diplomate, American Board of General Dentistry*

# ULCER



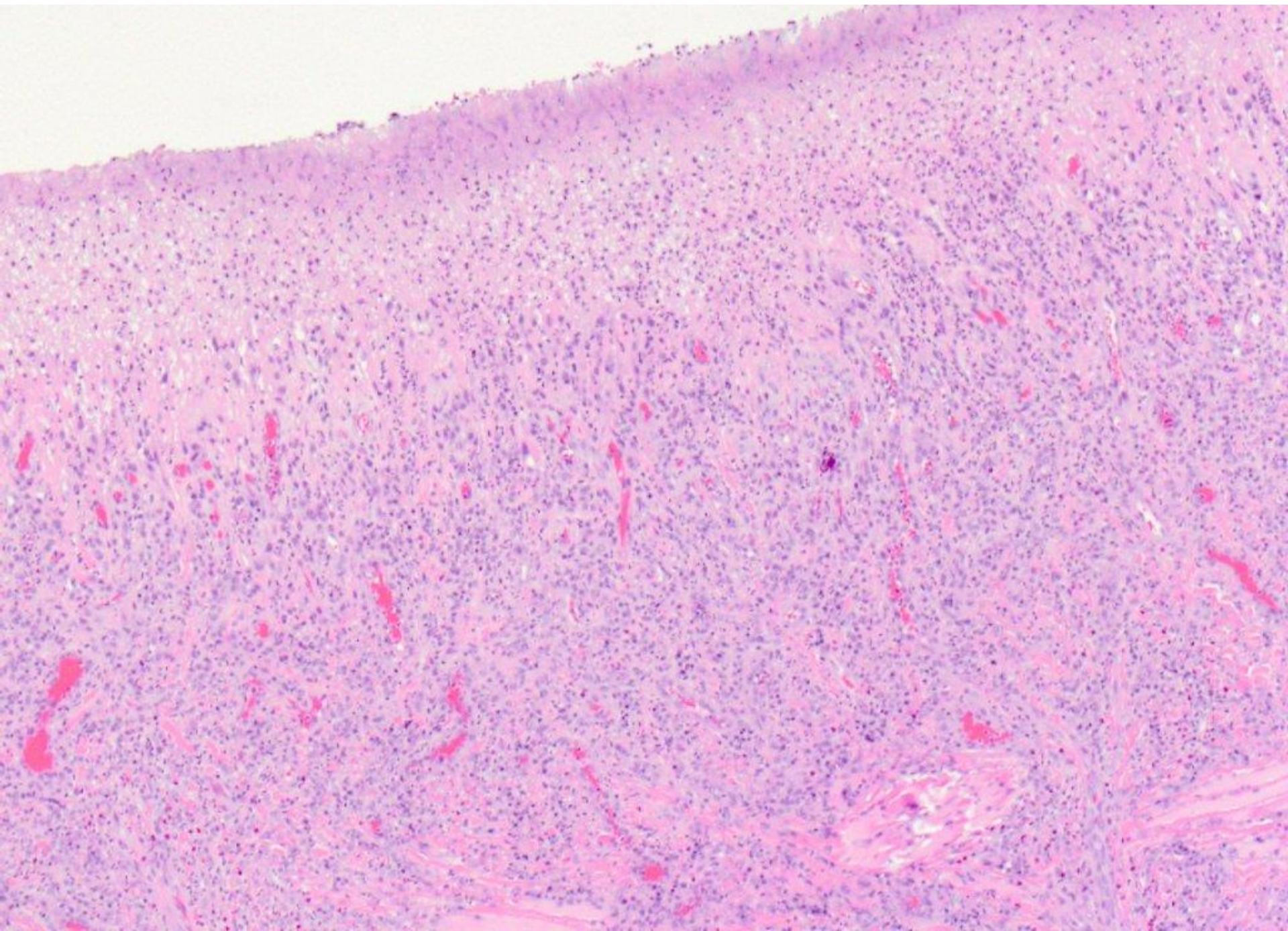


ULCER (LATERAL EDGE)



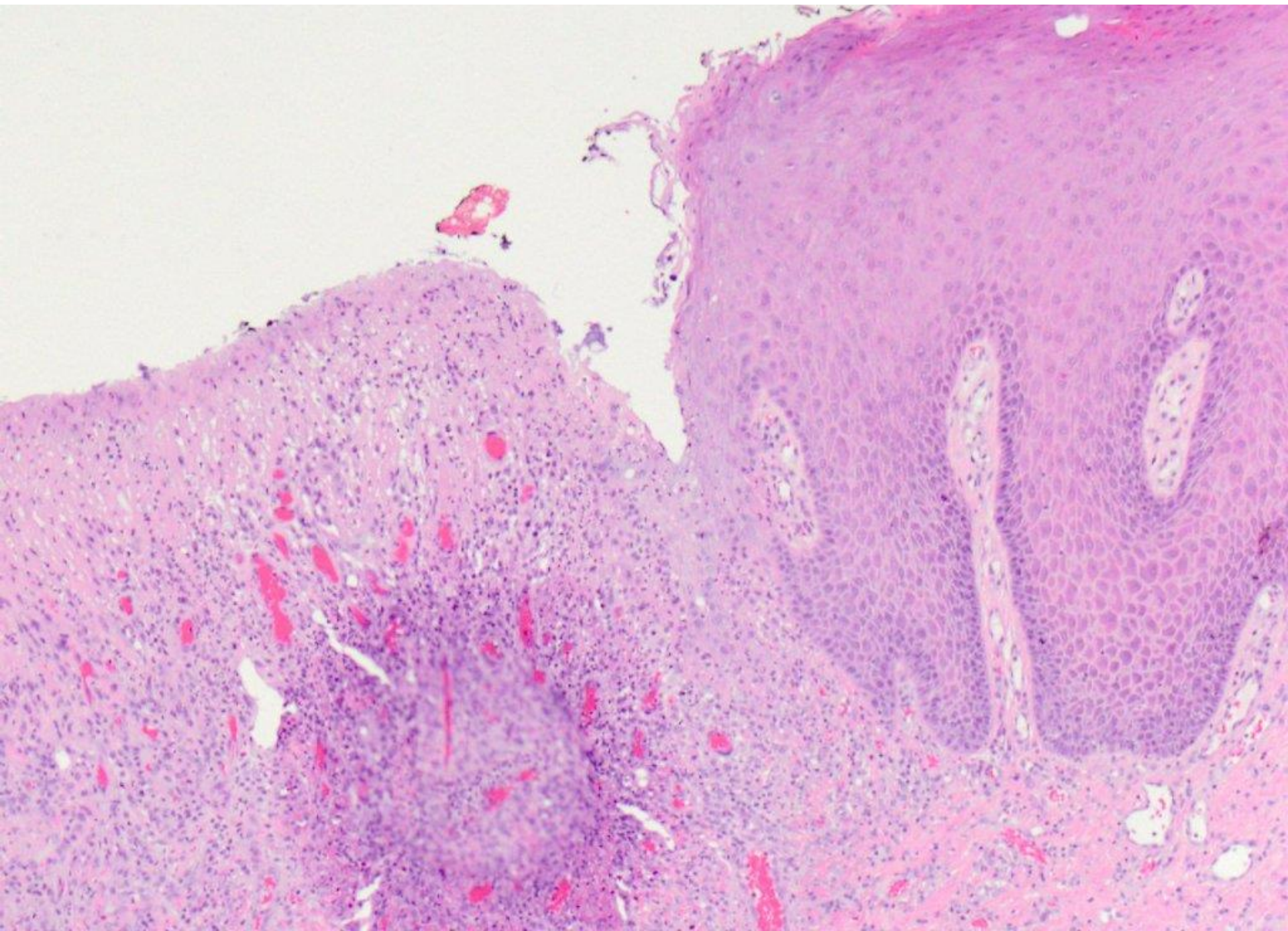


ULCER (CENTRAL PORTION)



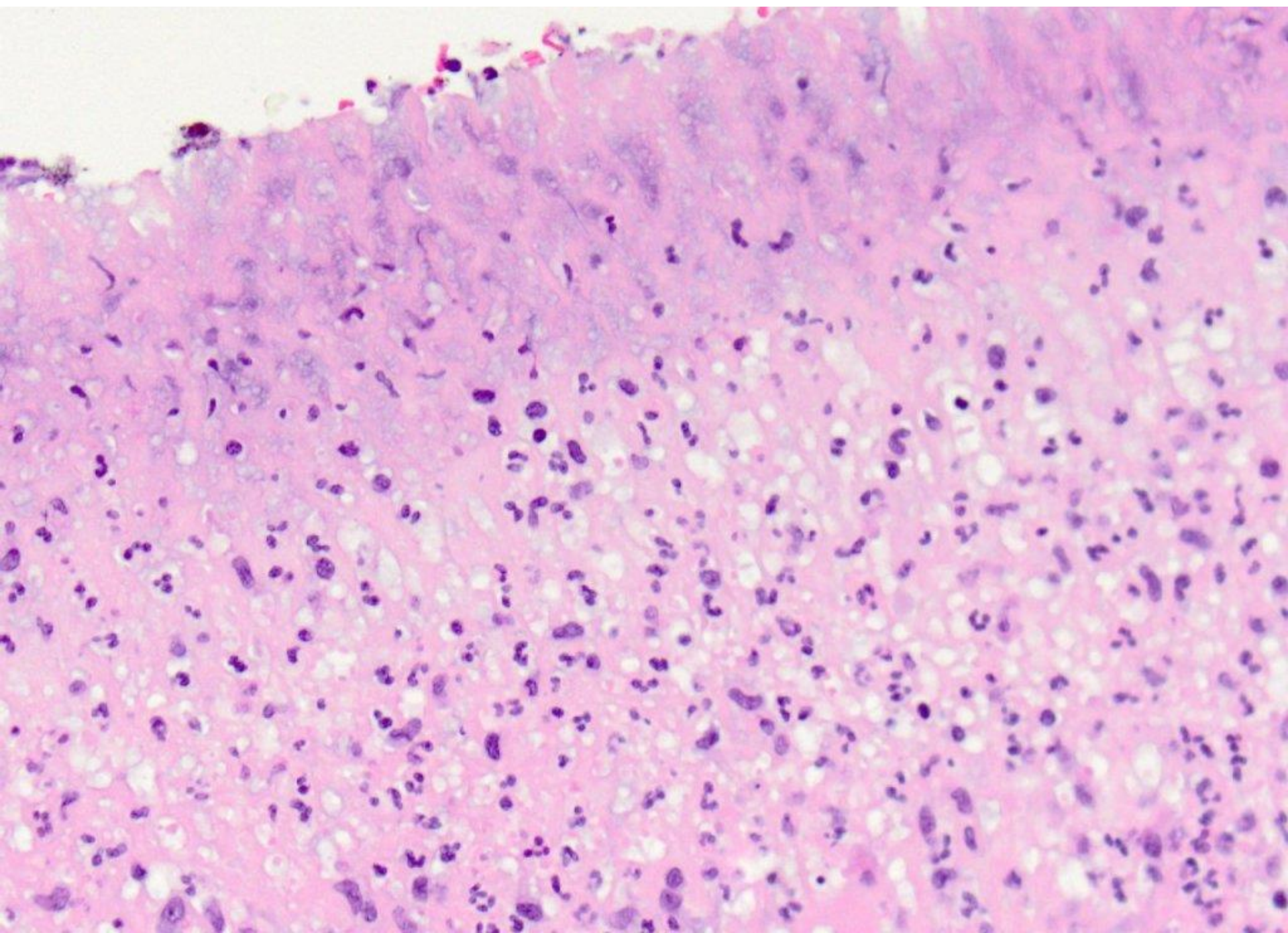


ULCER (LATERAL EDGE)



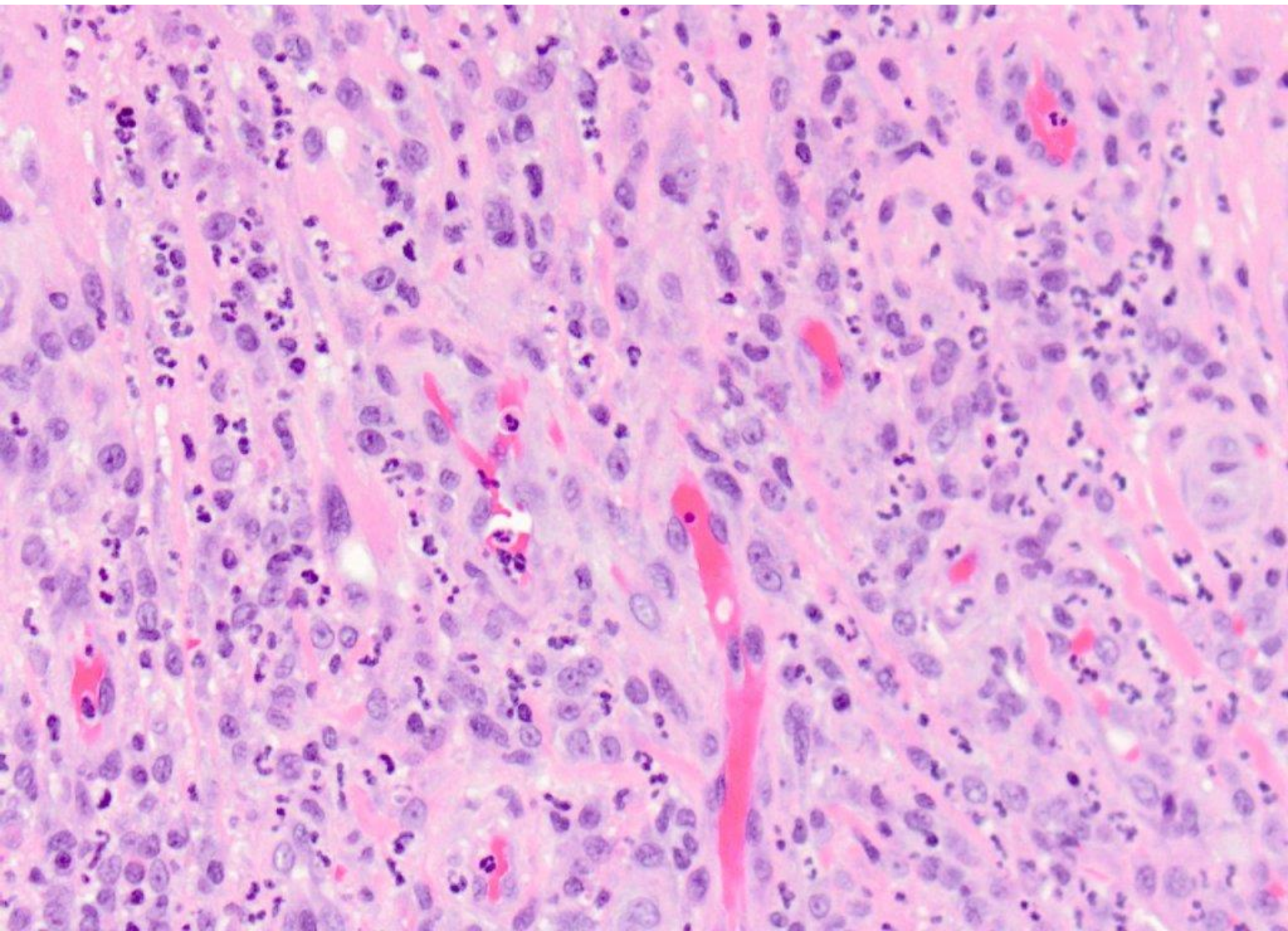


ULCER -- FIBRIN (TOP), ACUTE INFLAMMATION AND GRANULATION TISSUE (BOTTOM)



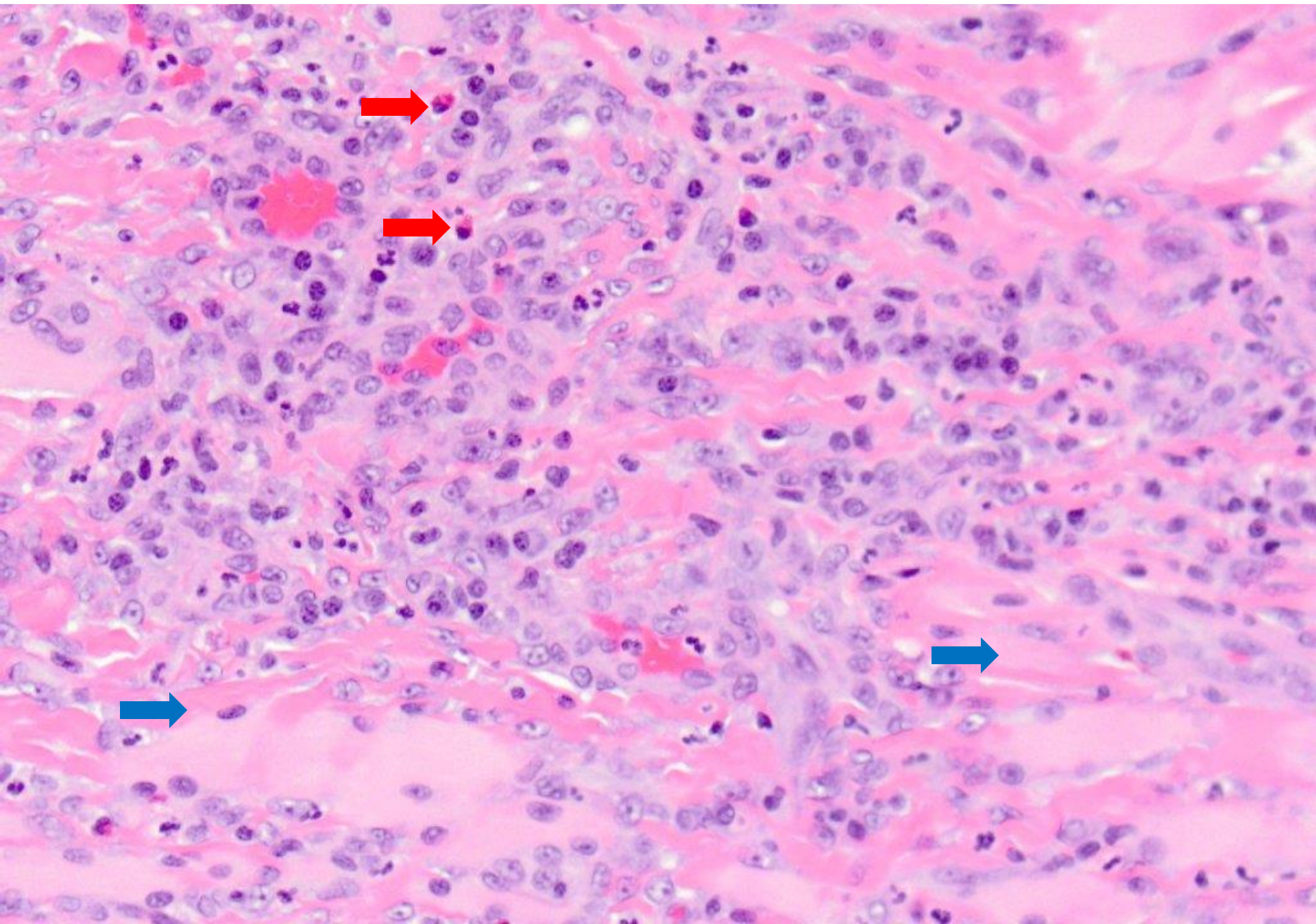


ULCER -- ACUTE INFLAMMATION AND GRANULATION TISSUE



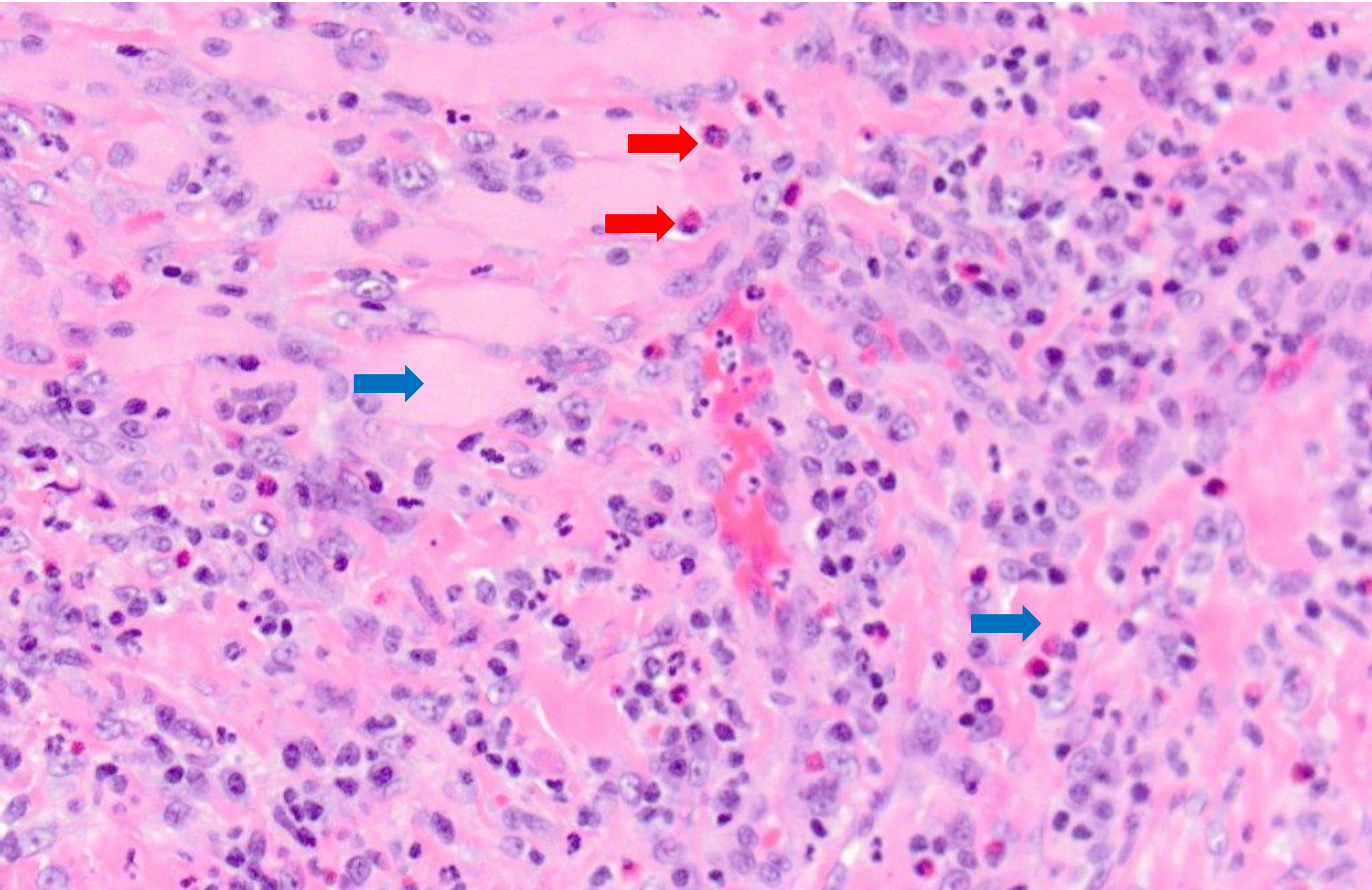


**ULCER -- ACUTE INFLAMMATION AND GRANULATION TISSUE  
EOSINOPHILS (RED ARROWS) AND SKELETAL MUSCLE (BLUE ARROWS)**





**ULCER -- ACUTE INFLAMMATION AND GRANULATION TISSUE  
EOSINOPHILS (RED ARROWS) AND SKELETAL MUSCLE (BLUE ARROWS)**

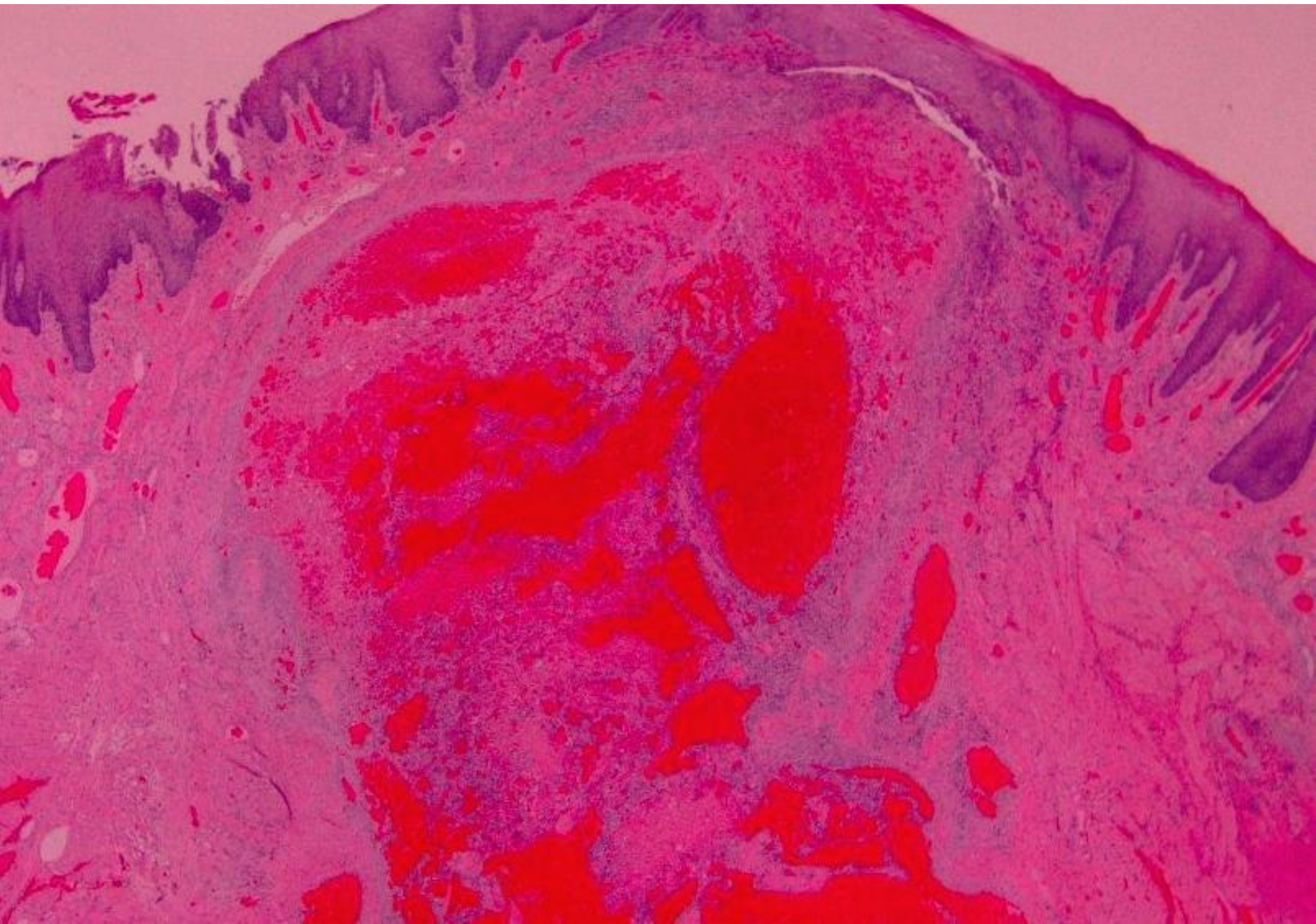


**THIS IS THE HISTOLOGY OF THE CO-CALLED *TUGSE* (TRAUMATIC ULCERATIVE GRANULOMA WITH STROMA EOSINOPHILIA OR *EOSINOPHILIC ULCER* OFTEN SEEN ON THE TRAUMATIZED TONGUE)**



## HEMATOMA

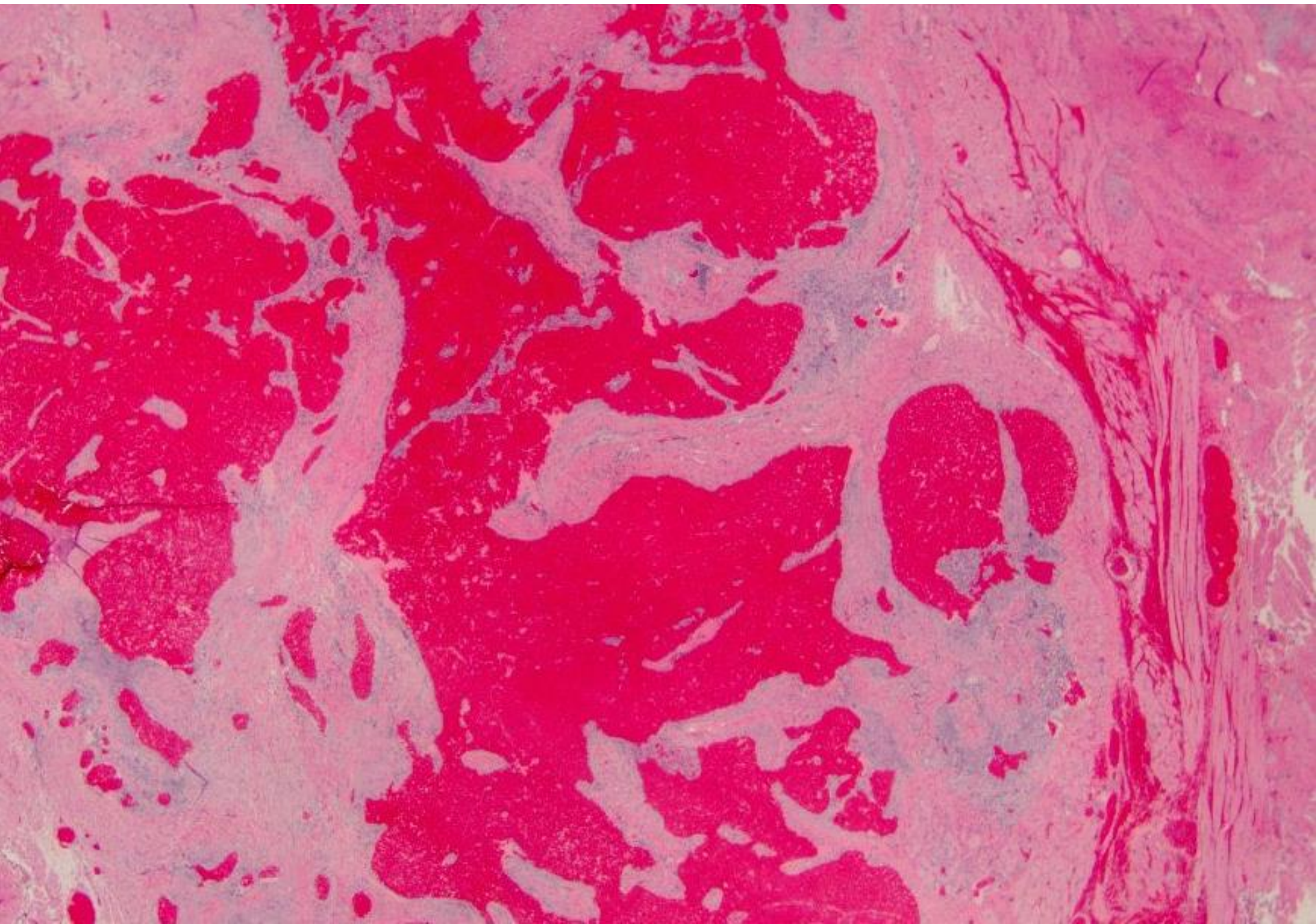
(BLOOD EXTRAVASATED INTO TISSUES; WILL NOT BLANCH WITH *DIASCOPYY* OR STRETCHING)





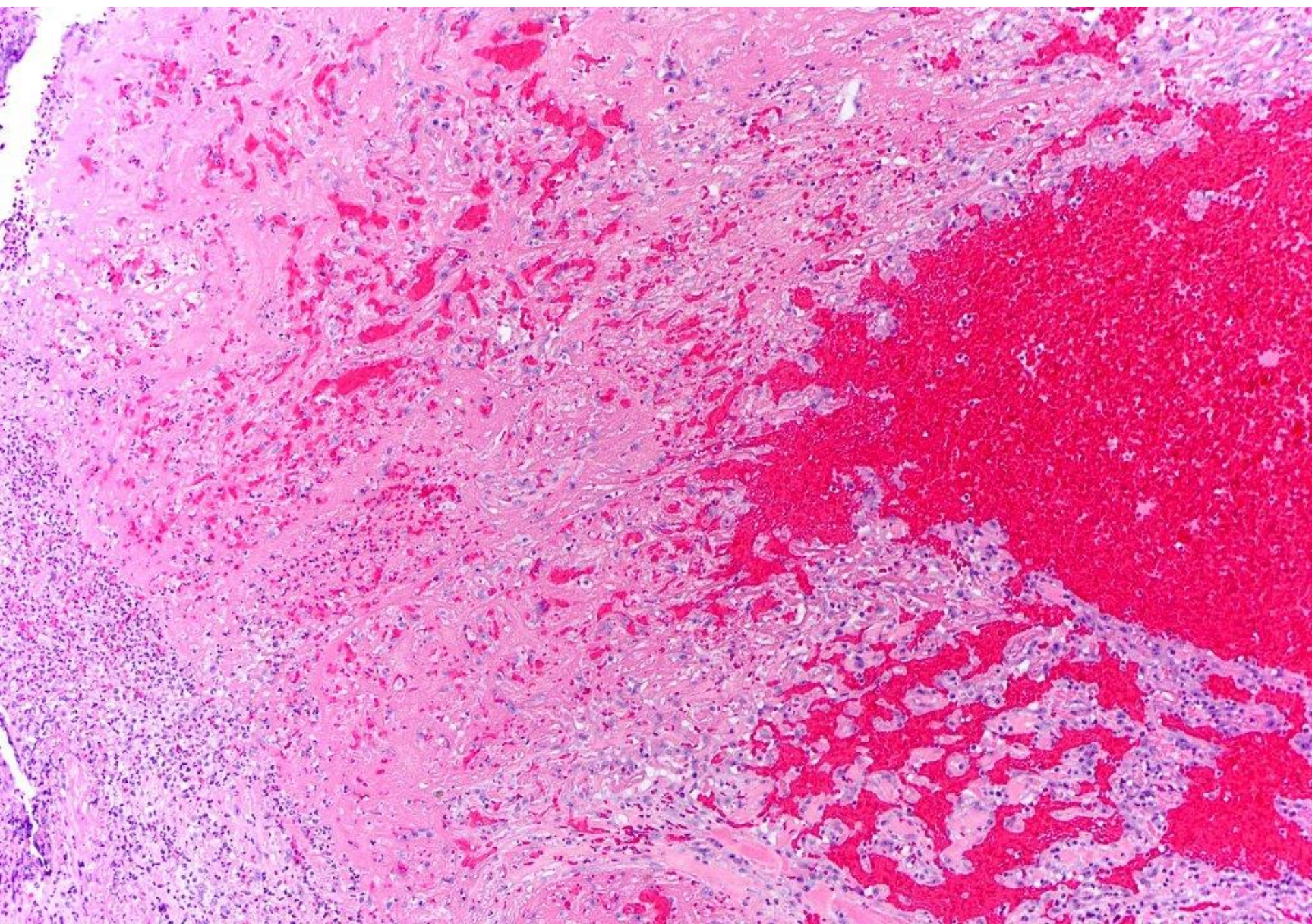
## HEMATOMA

FIBRIN CAN BE SEEN AS AMORPHOUS PINK MATERIAL AT THIS LOW POWER



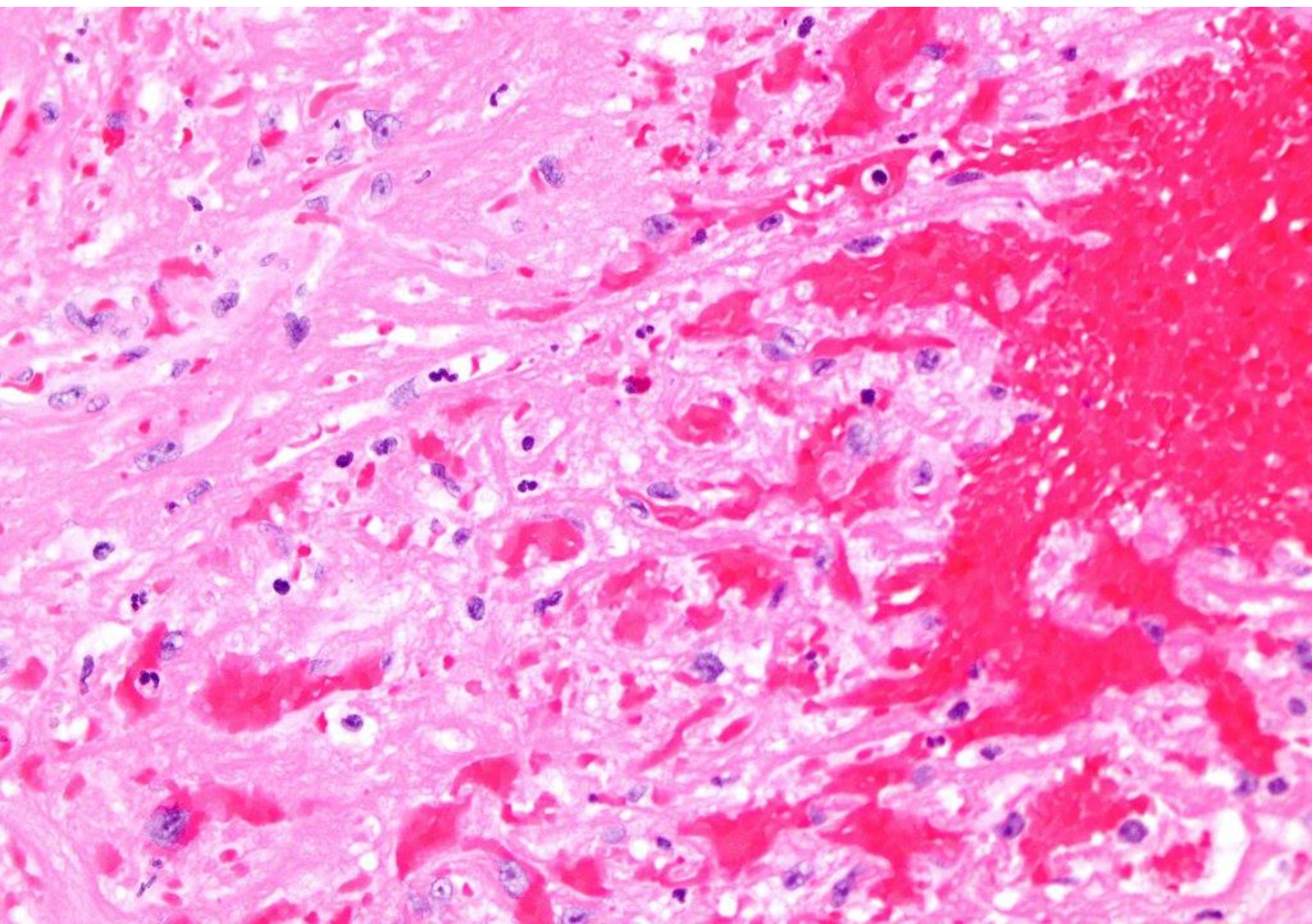


**HEMATOMA**  
**HEMORRHAGE (RIGHT), FIBRIN (CENTER), GRANULAITON TISSUE (LEFT)**



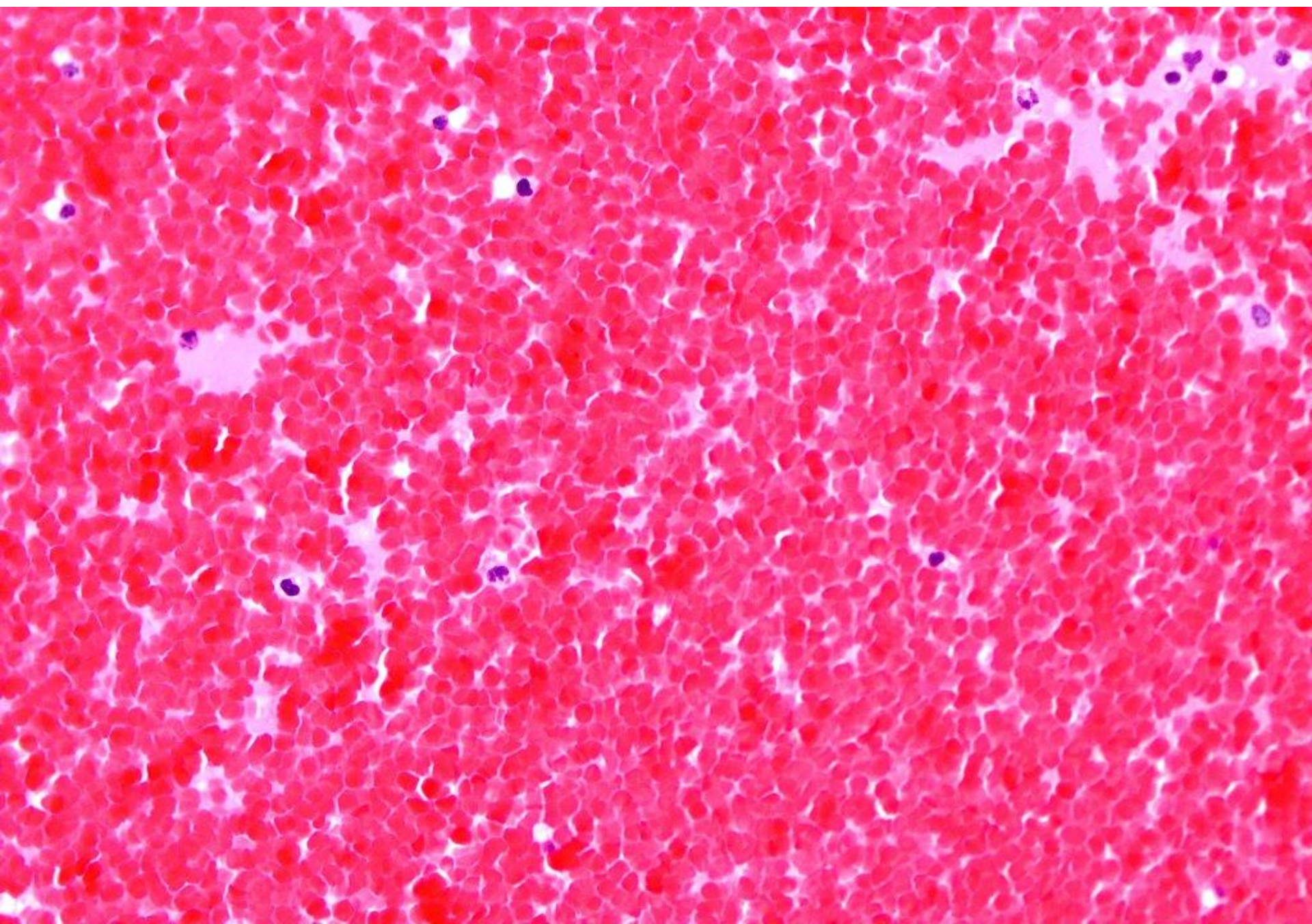


**HEMATOMA  
PREDOMINANTLY FIBRIN**





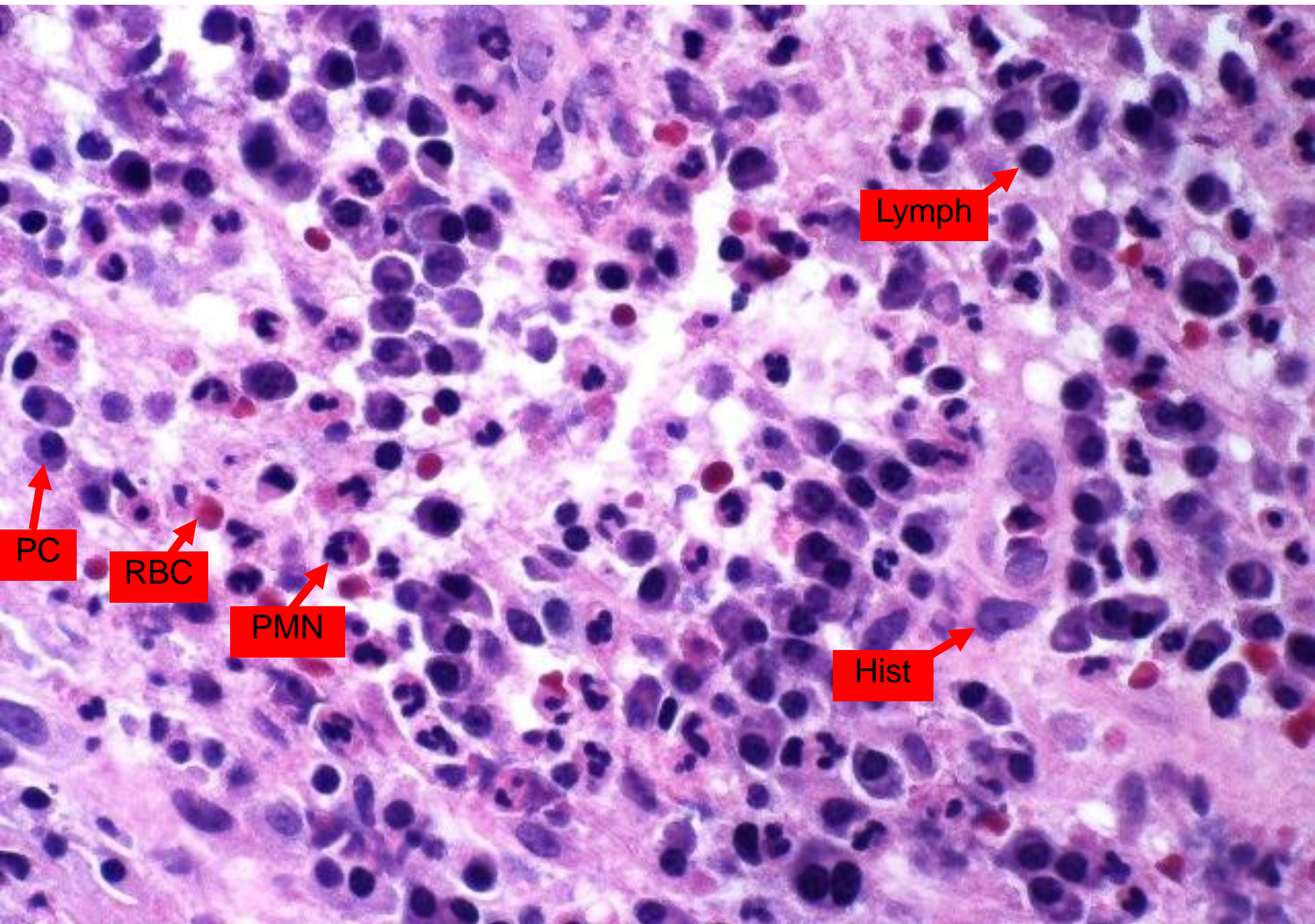
**HEMATOMA**  
**HEMORRHAGE (PREDOMINANTLY ERYTHROCYTES; A FEW LEUKOCYTES SEEN)**





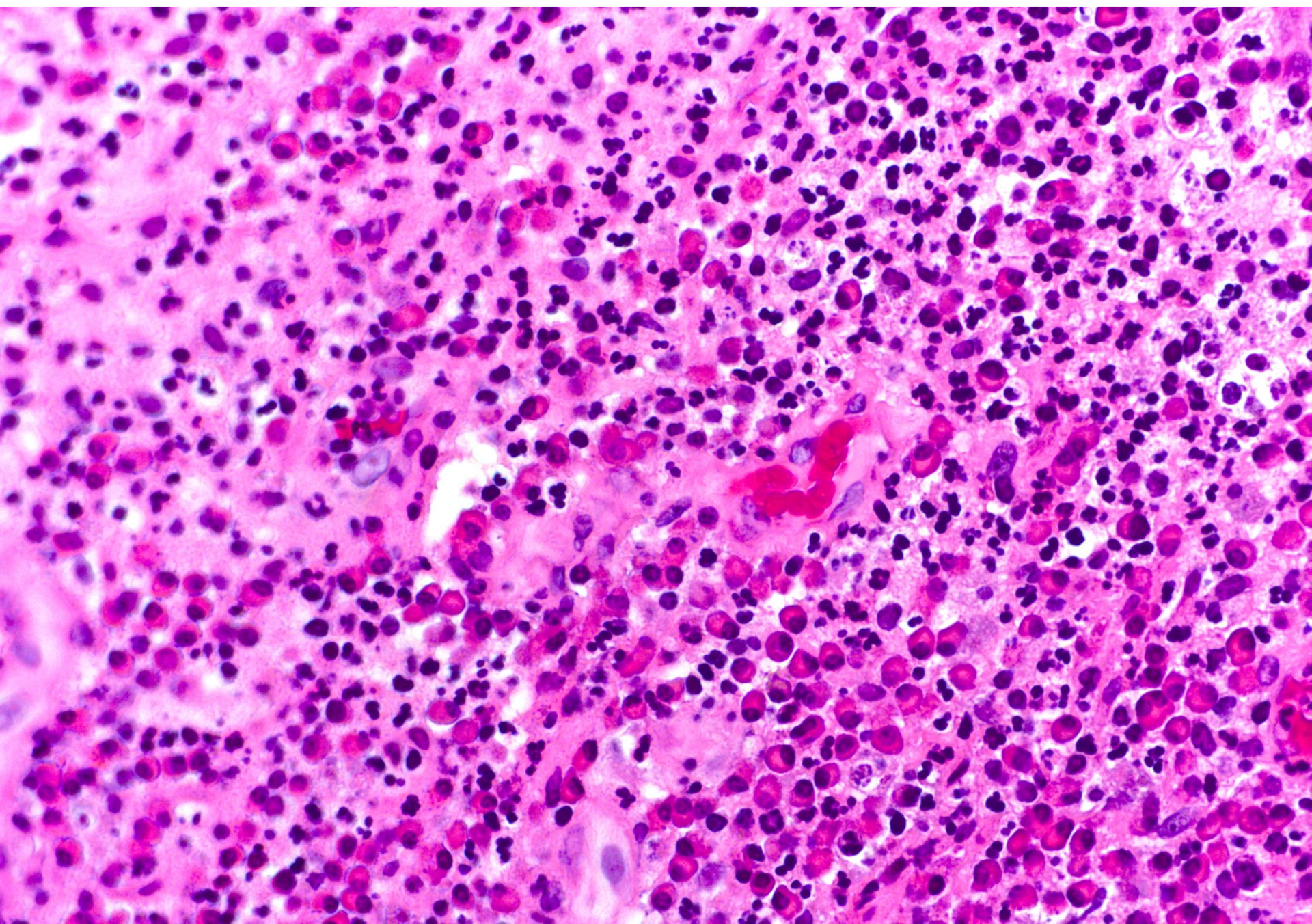
## INFLAMMATION

PC = PLASMA CELL, RBC = ERYTHROCYTE, PMN = NEUTROPHIL, LYMPH = LYMPHOCYTE, HIST = HISTIOCYTE



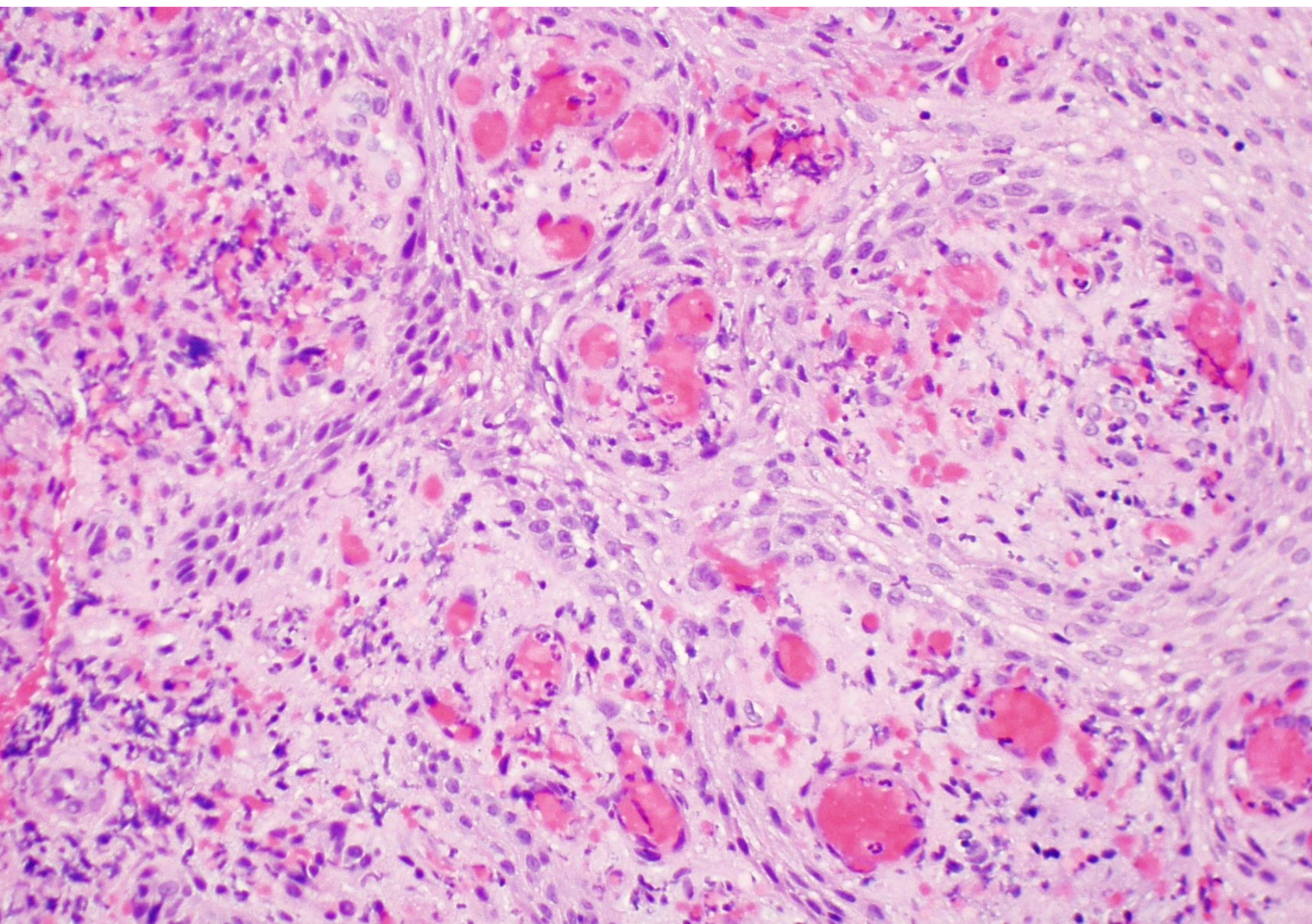


**INFLAMMATION**  
**(PREDOMINANTLY ACUTE INFLAMMATION WITH NUMEROUS PLASMA CELLS)**



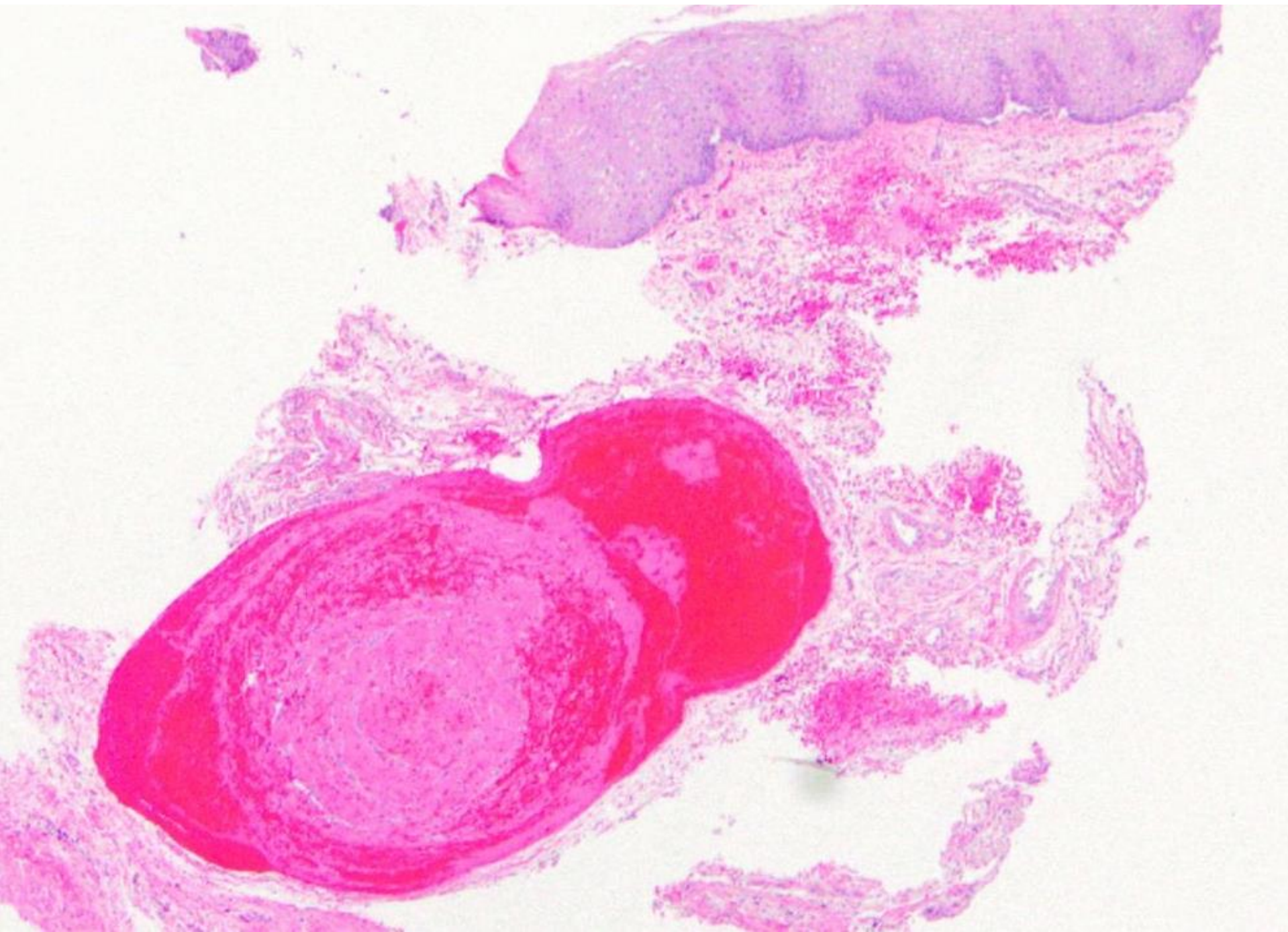


**GRANULATION TISSUE  
(VASCULAR, HEMORRHAGIC)**





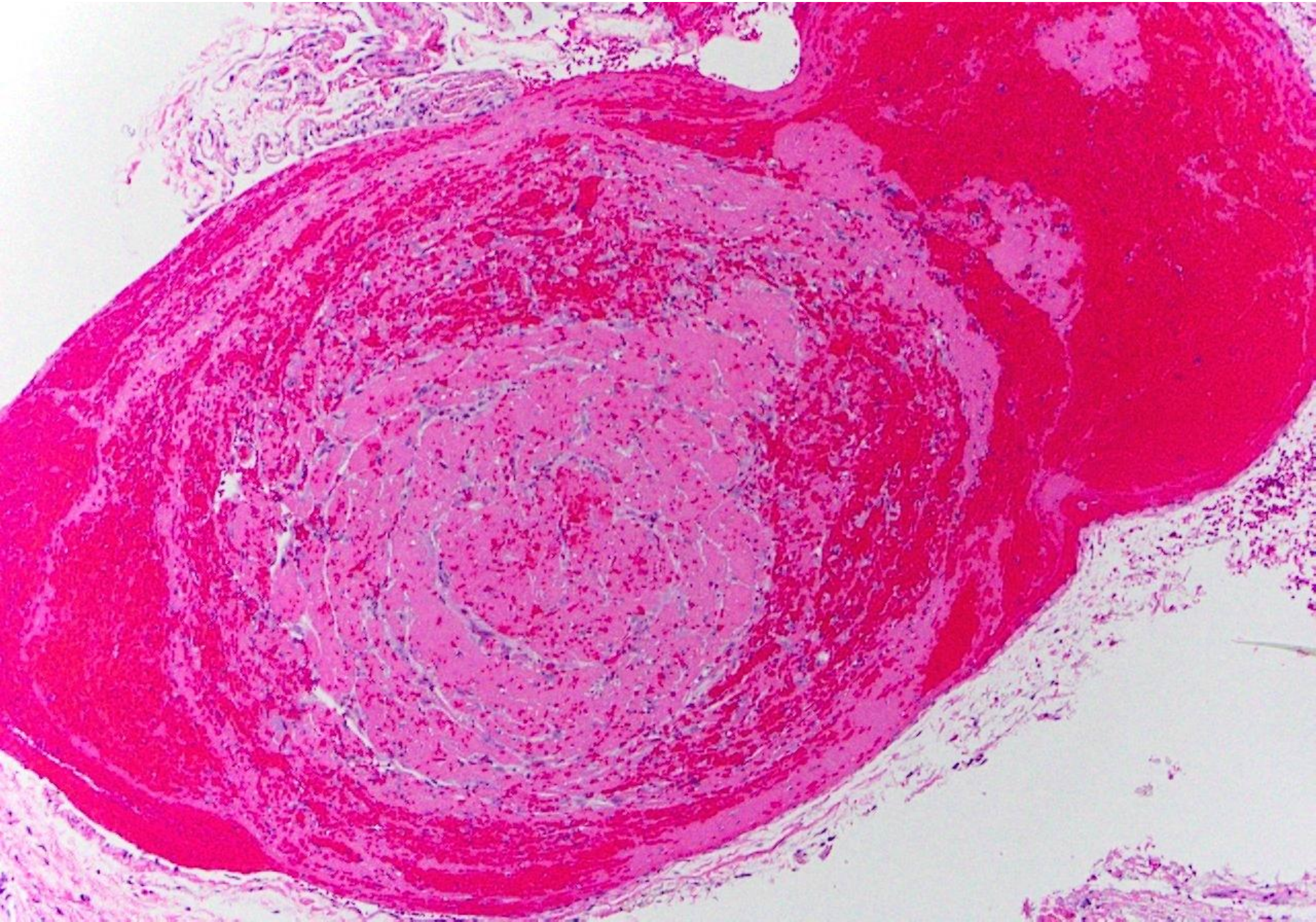
**VARIX WITH ORGANIZING THROMBUS (SURFACE MUCOSA AT TOP)**





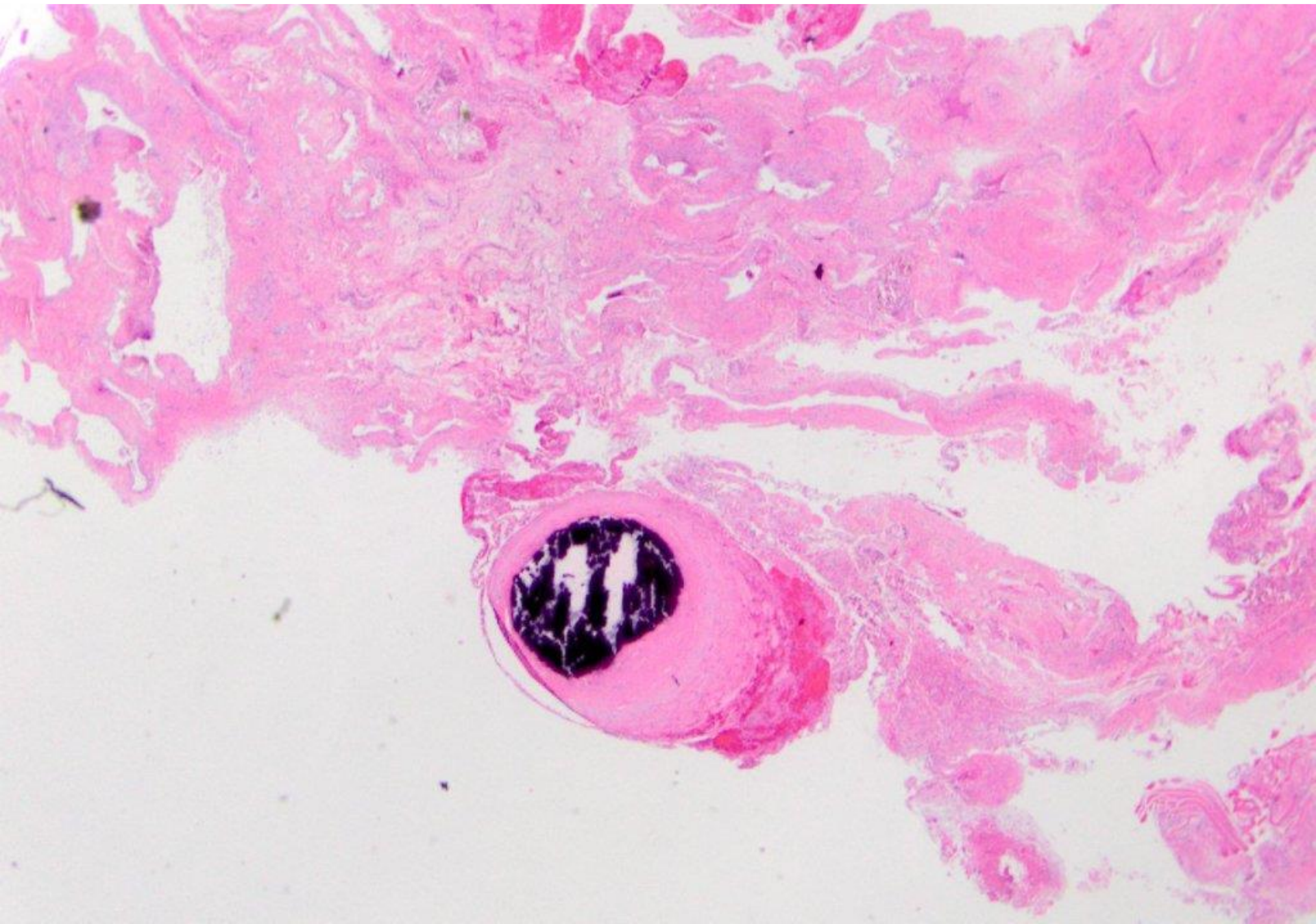
**VARIX WITH ORGANIZING THROMBUS**

**INCREMENTAL LINES OF ZAHN CAN BE SEEN AS ALTERNATING LINES OF HEMORRHAGE AND FIBRIN**



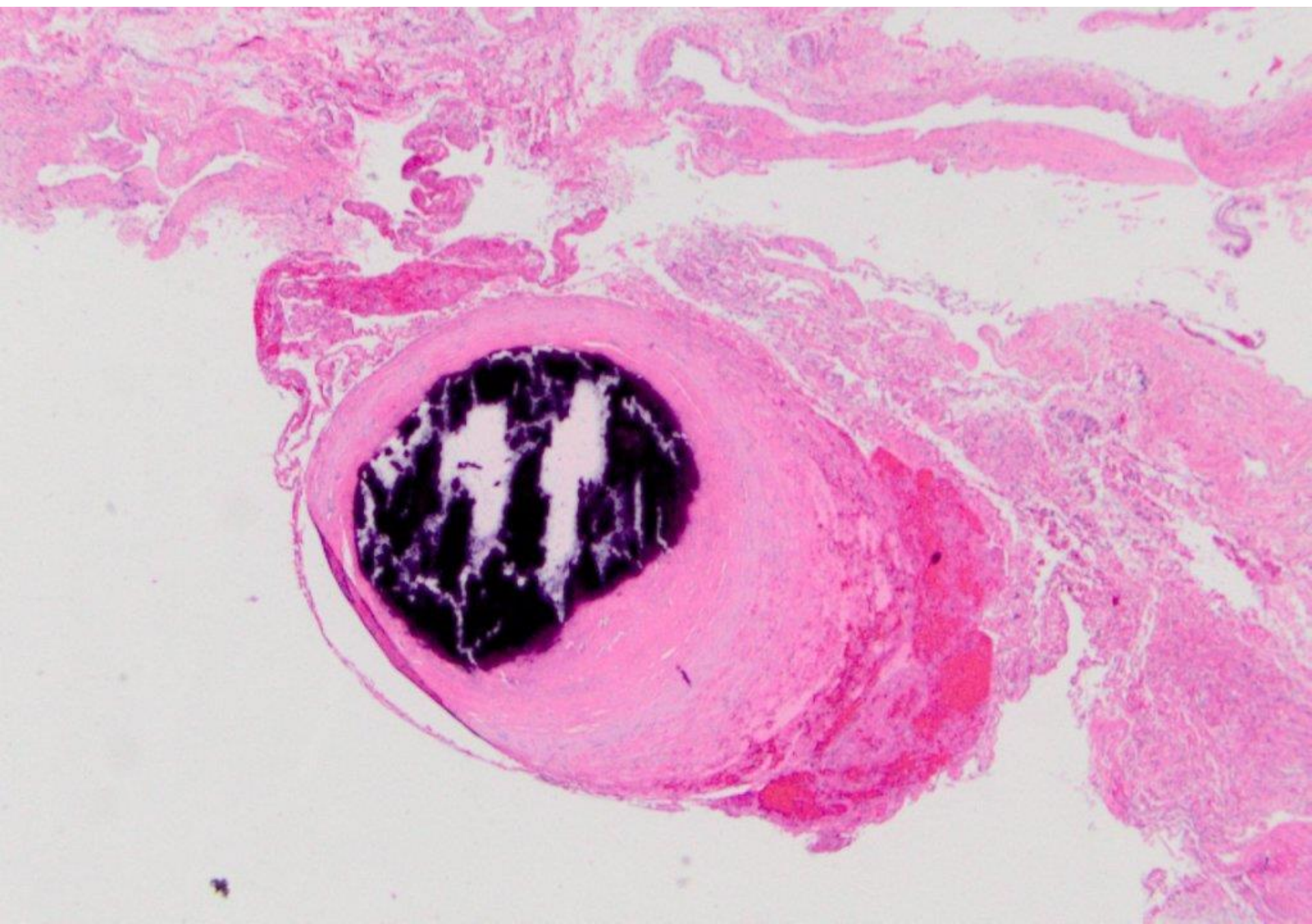


**VARIX WITH ORGANIZING THROMBUS**  
**THE THROMBUS IS PARTIALLY CALCIFIED (*PHLEBOLITH*)**



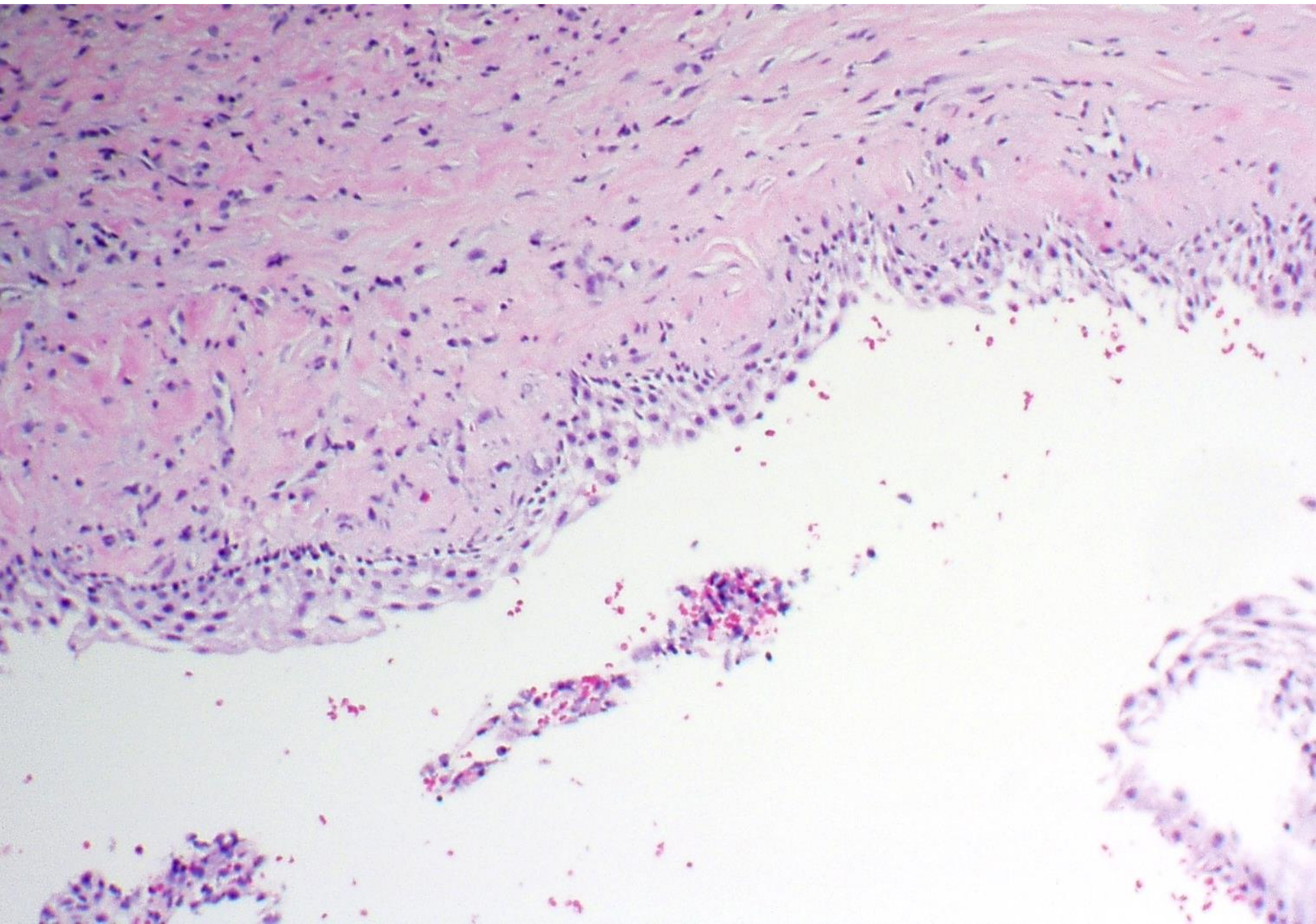


**VARIX WITH ORGANIZING THROMBUS**  
**THE THROMBUS IS PARTIALLY CALCIFIED (*PHLEBOLITH*)**



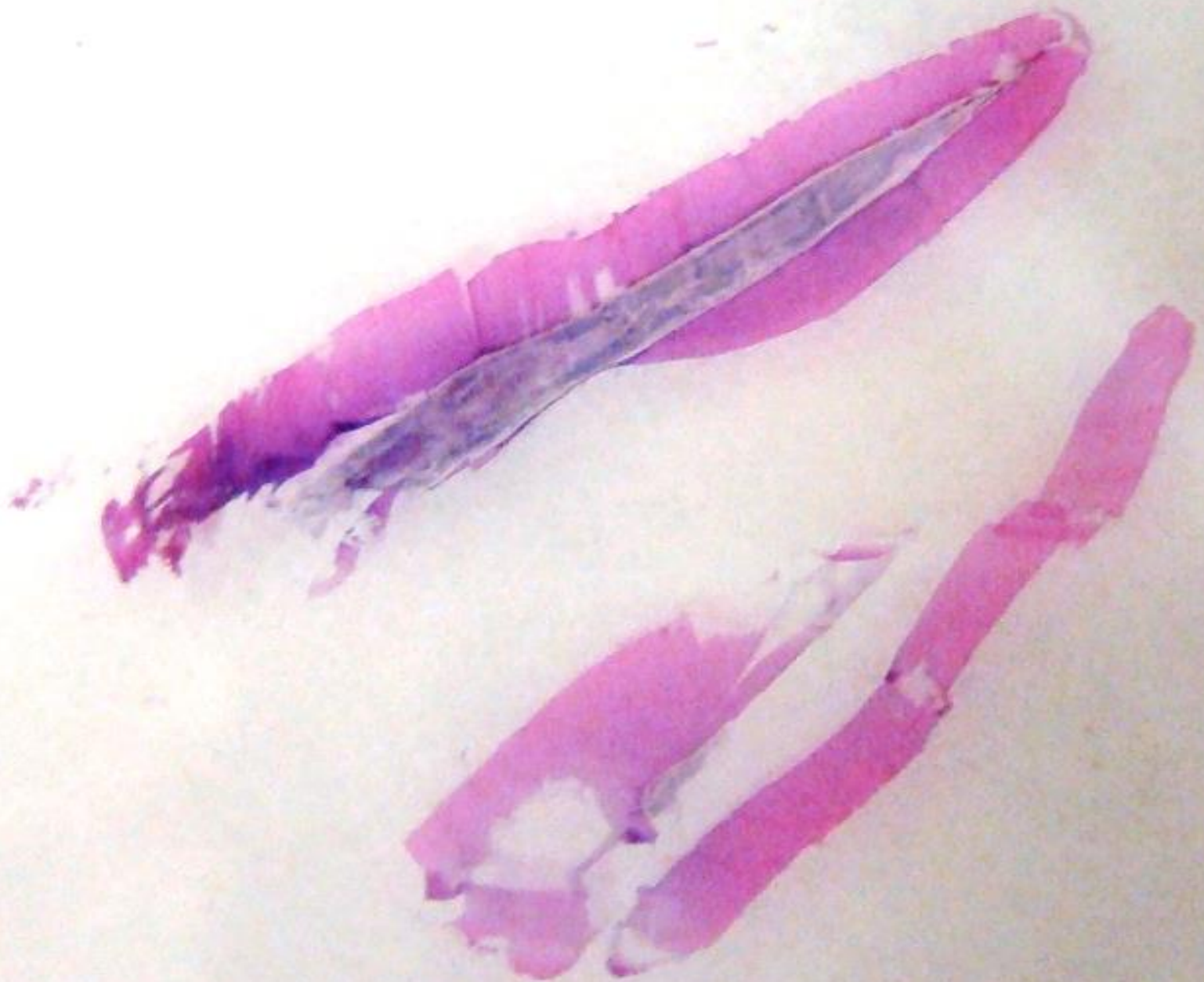

**CYST**  
**(AN EPITHELIAL LINED CAVITY)**



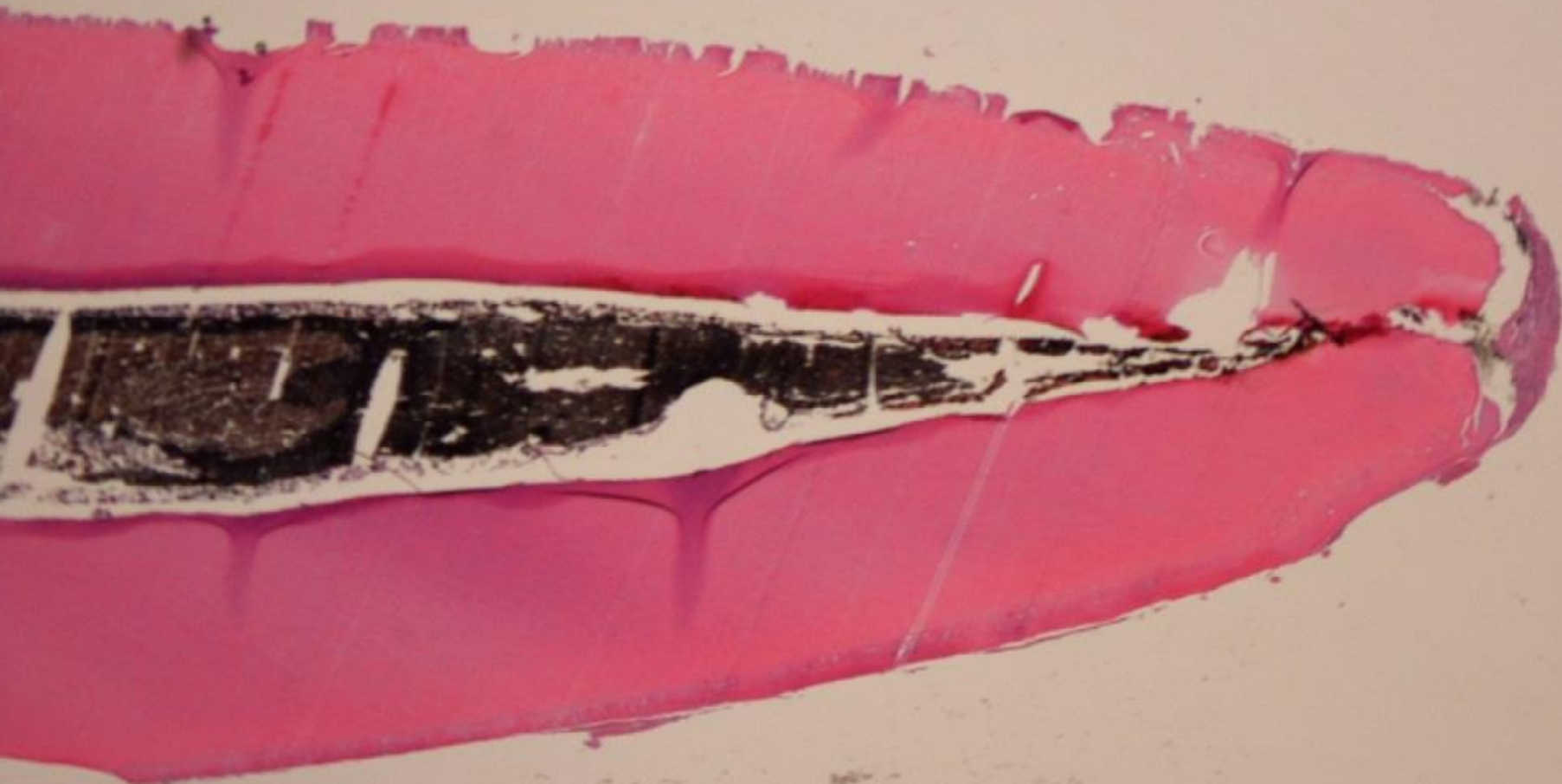


extracted tooth with root canal



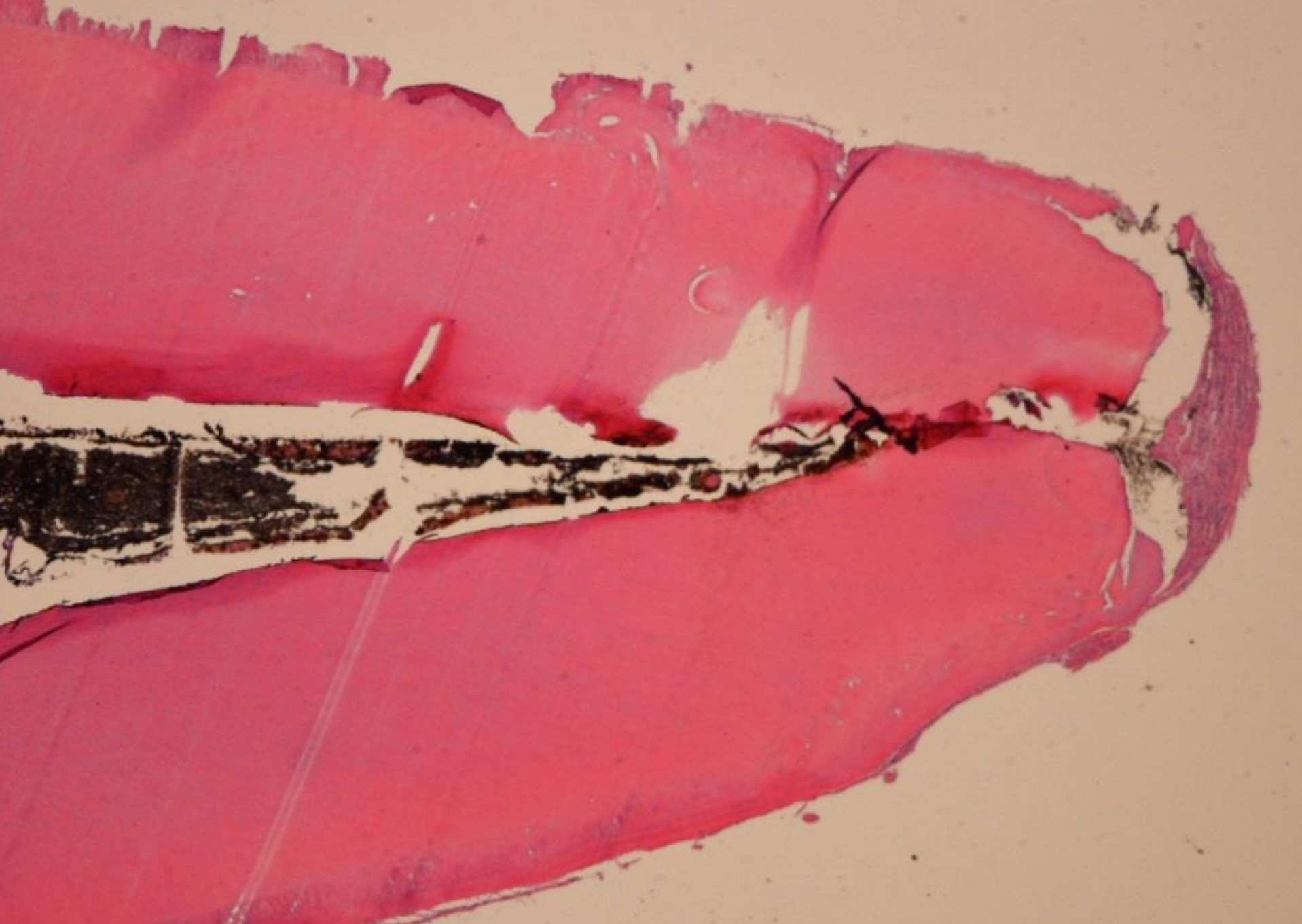
"1x" on the slide





uncondensed





uncondensed





uncondensed






uncondensed, "polarized"





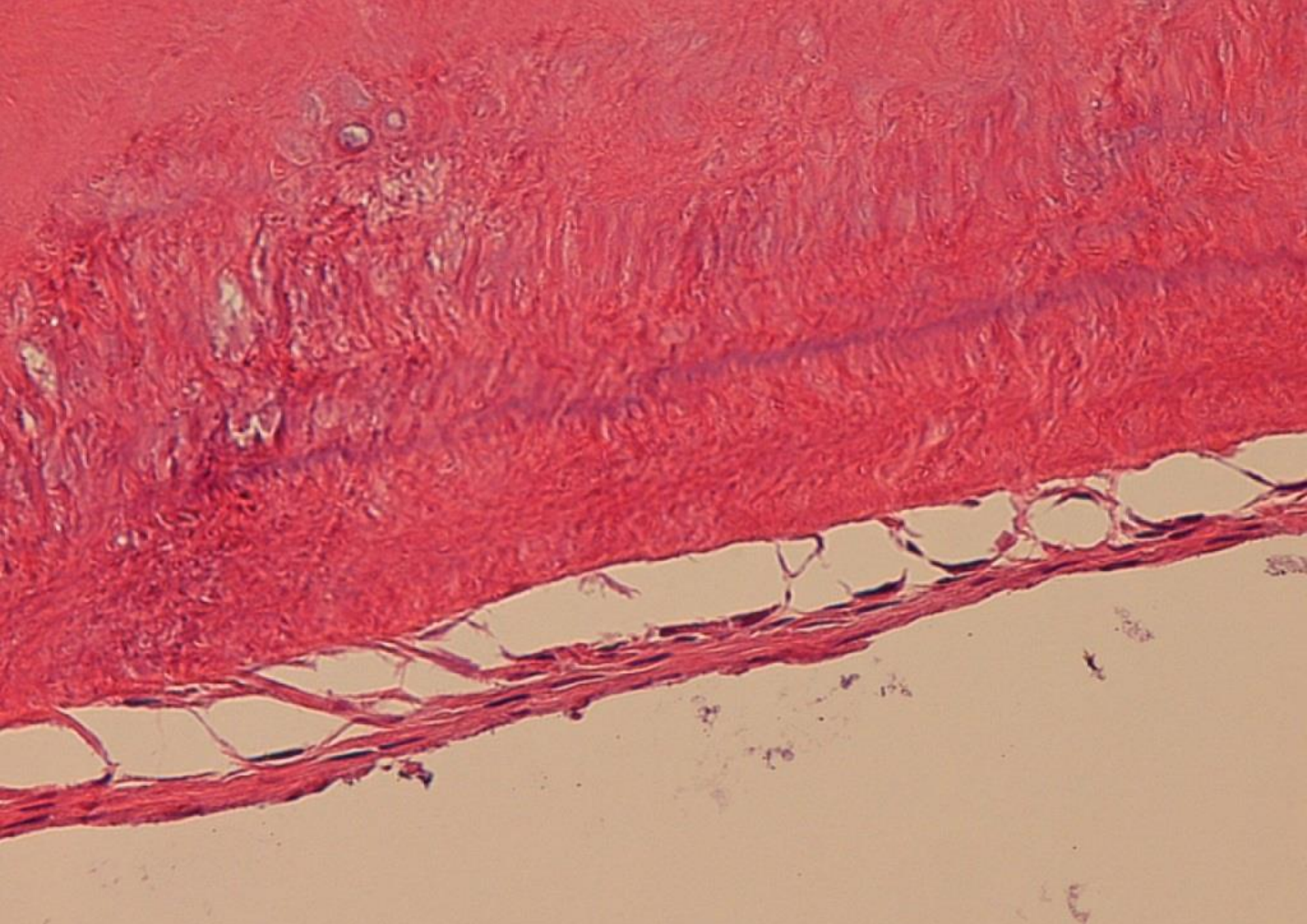
uncondensed





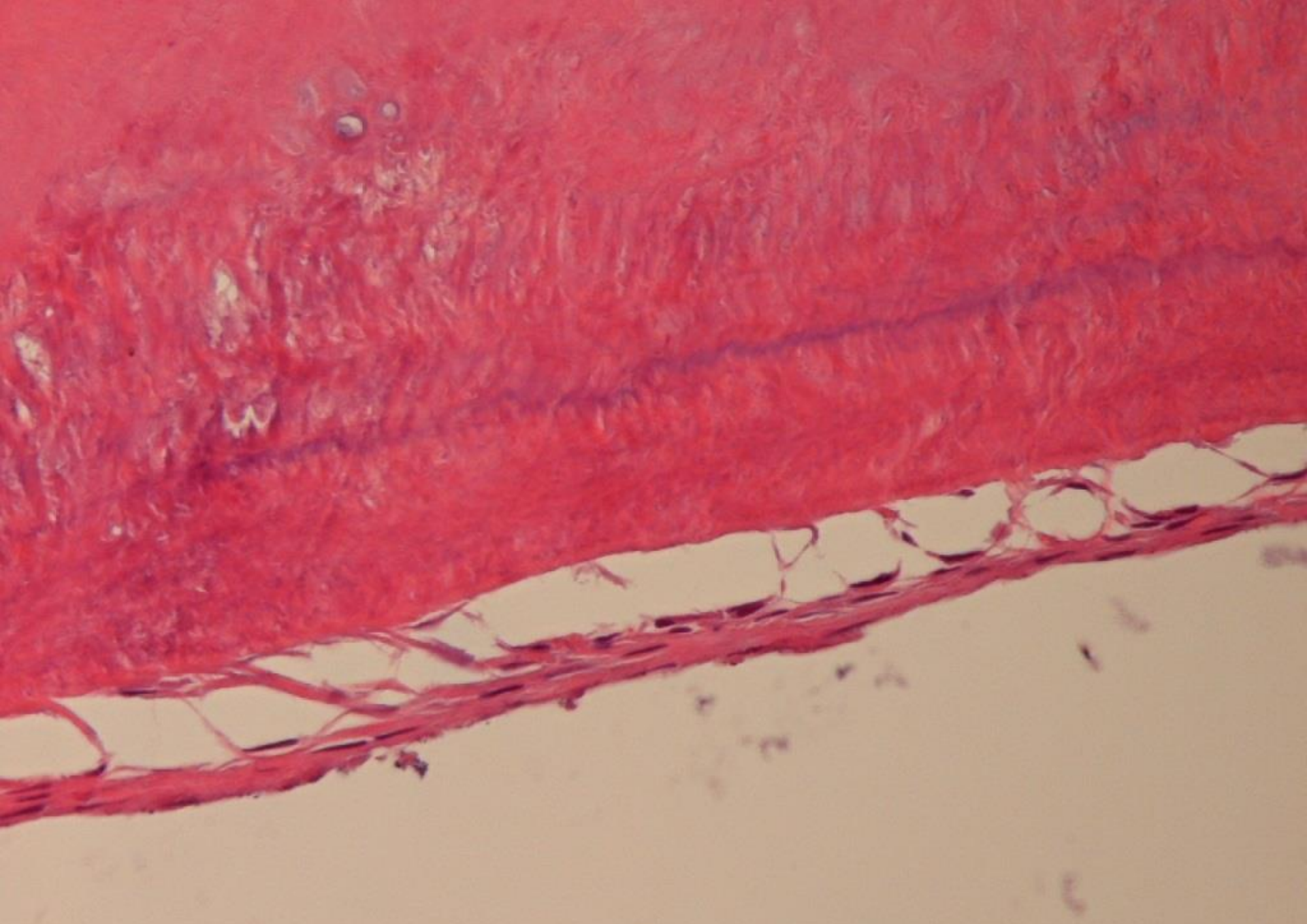
condensed





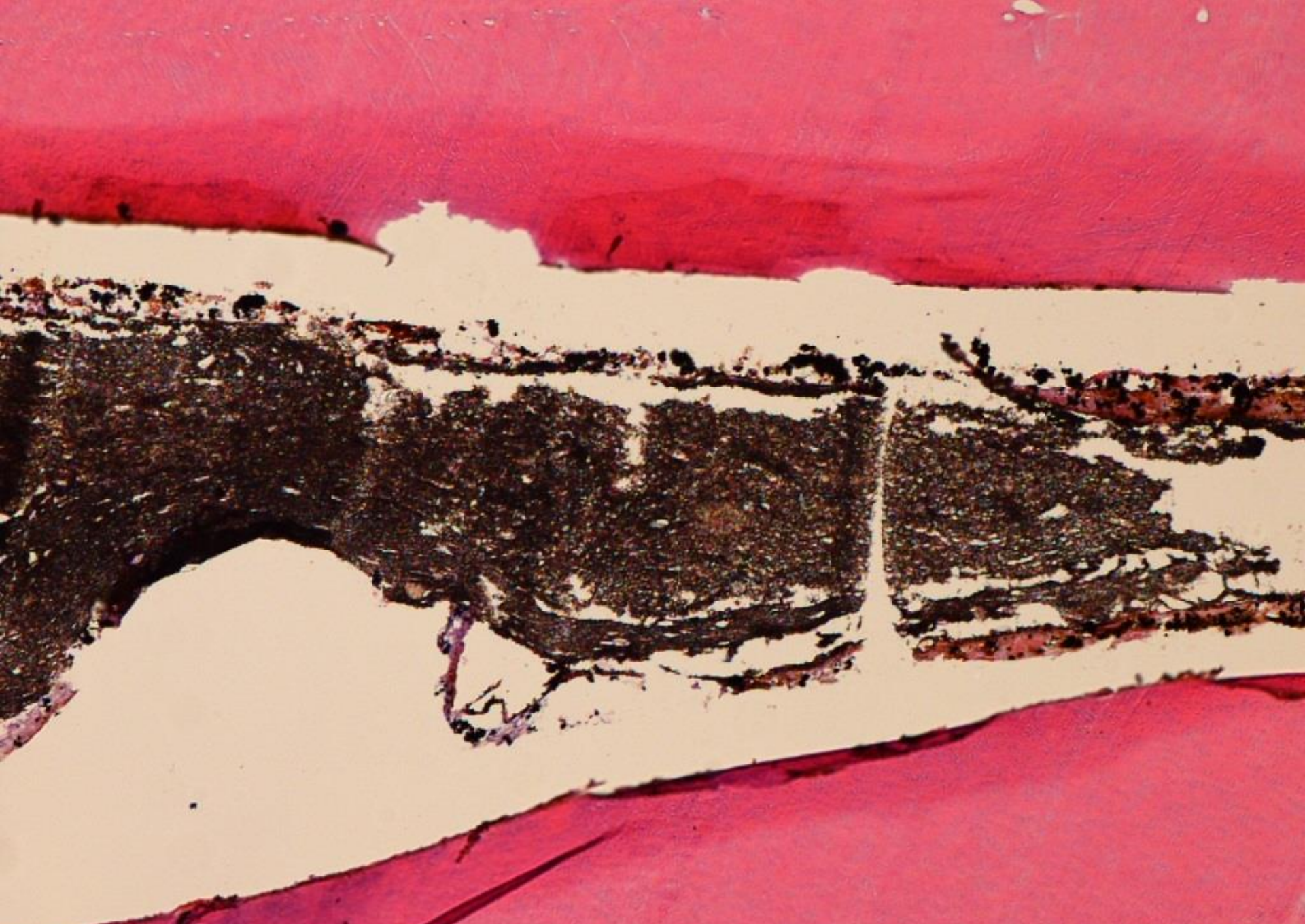
uncondensed





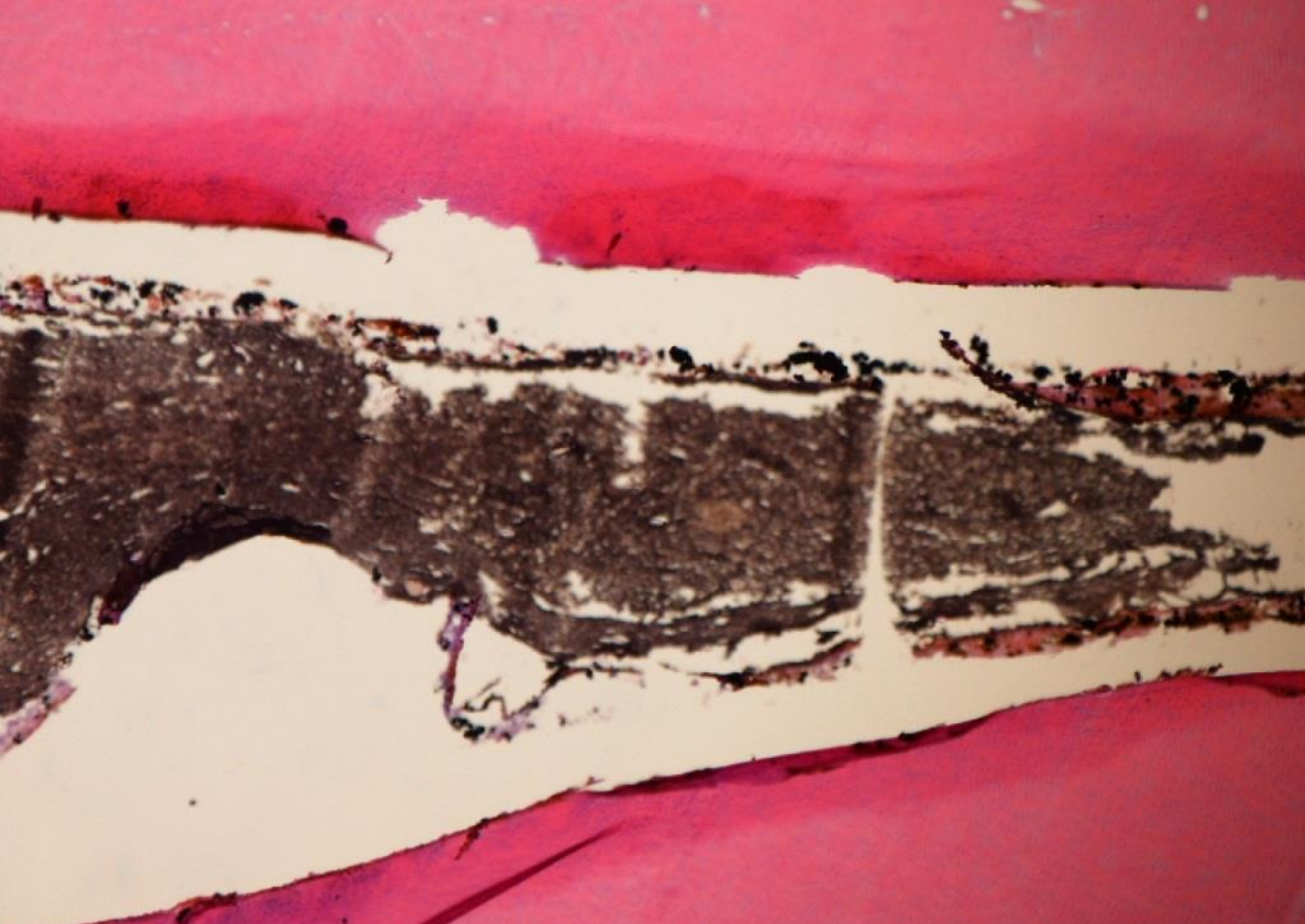
condensed






uncondensed





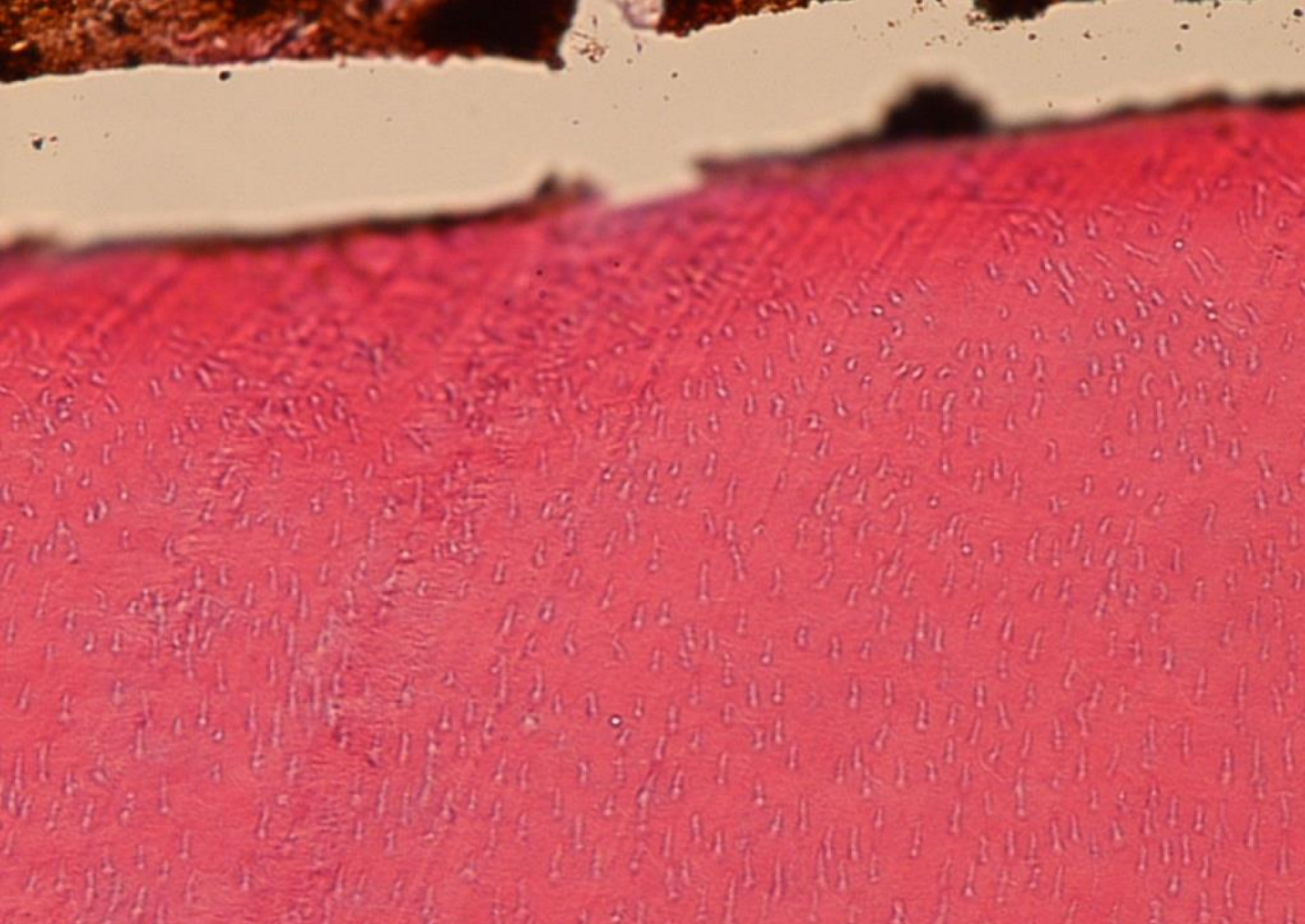
condensed





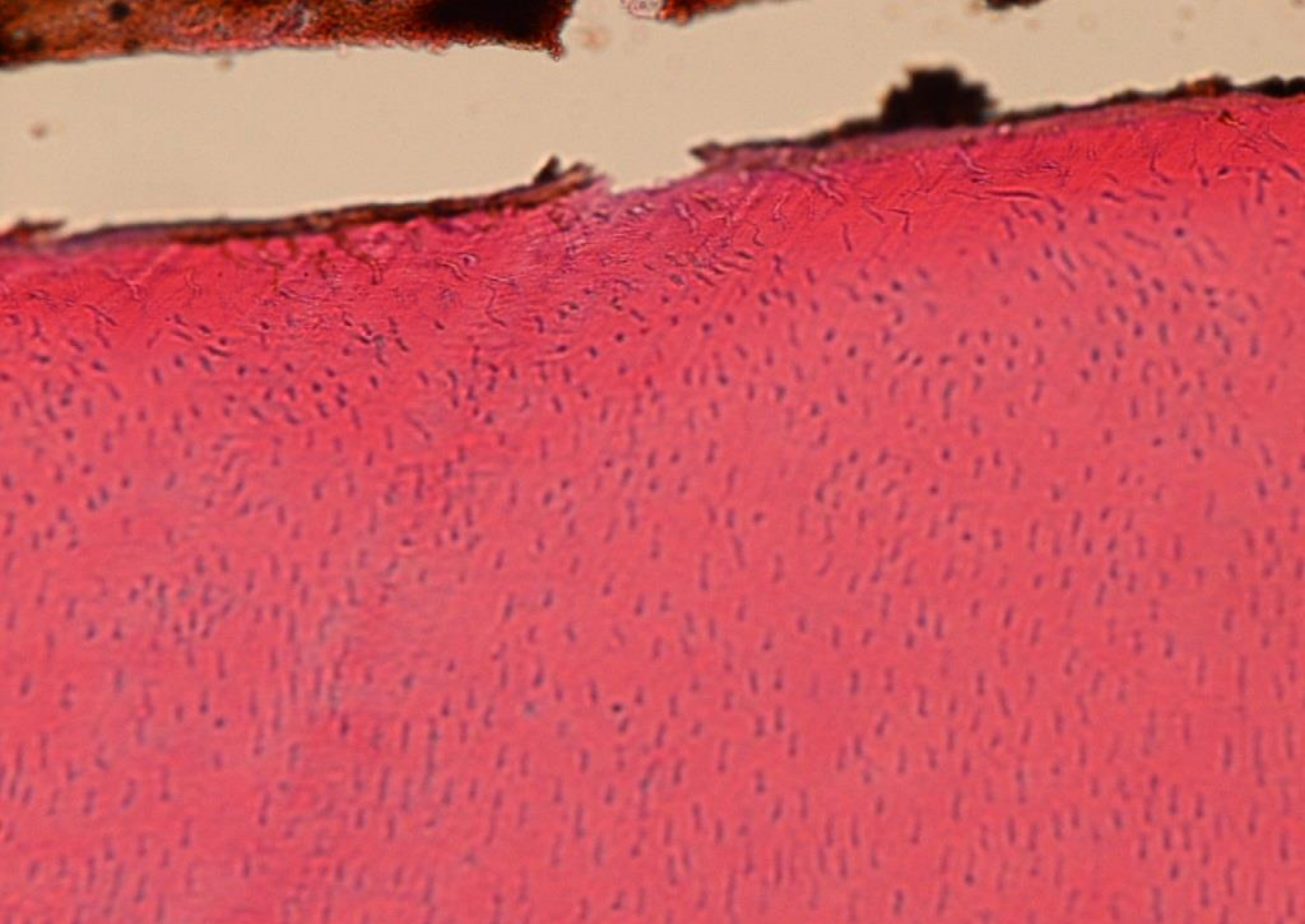
uncondensed, “polarized”





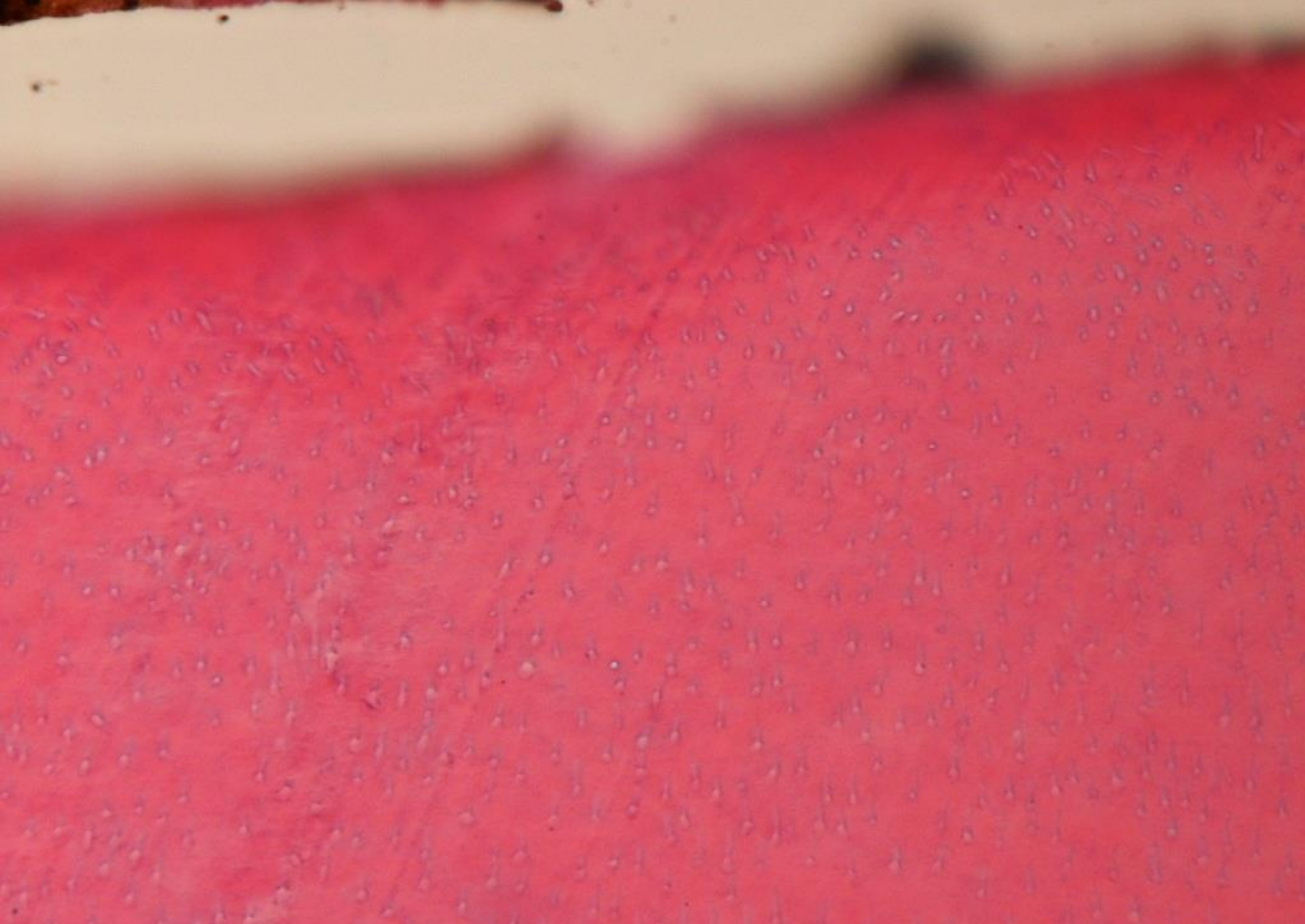
uncondensed dentin-instrumentation interface (high focus)





uncondensed dentin-instrumentation interface (low focus)





condensed dentin-instrumentation interface (high focus)





condensed dentin-instrumentation interface (low focus)





uncondensed dentin (high focus)





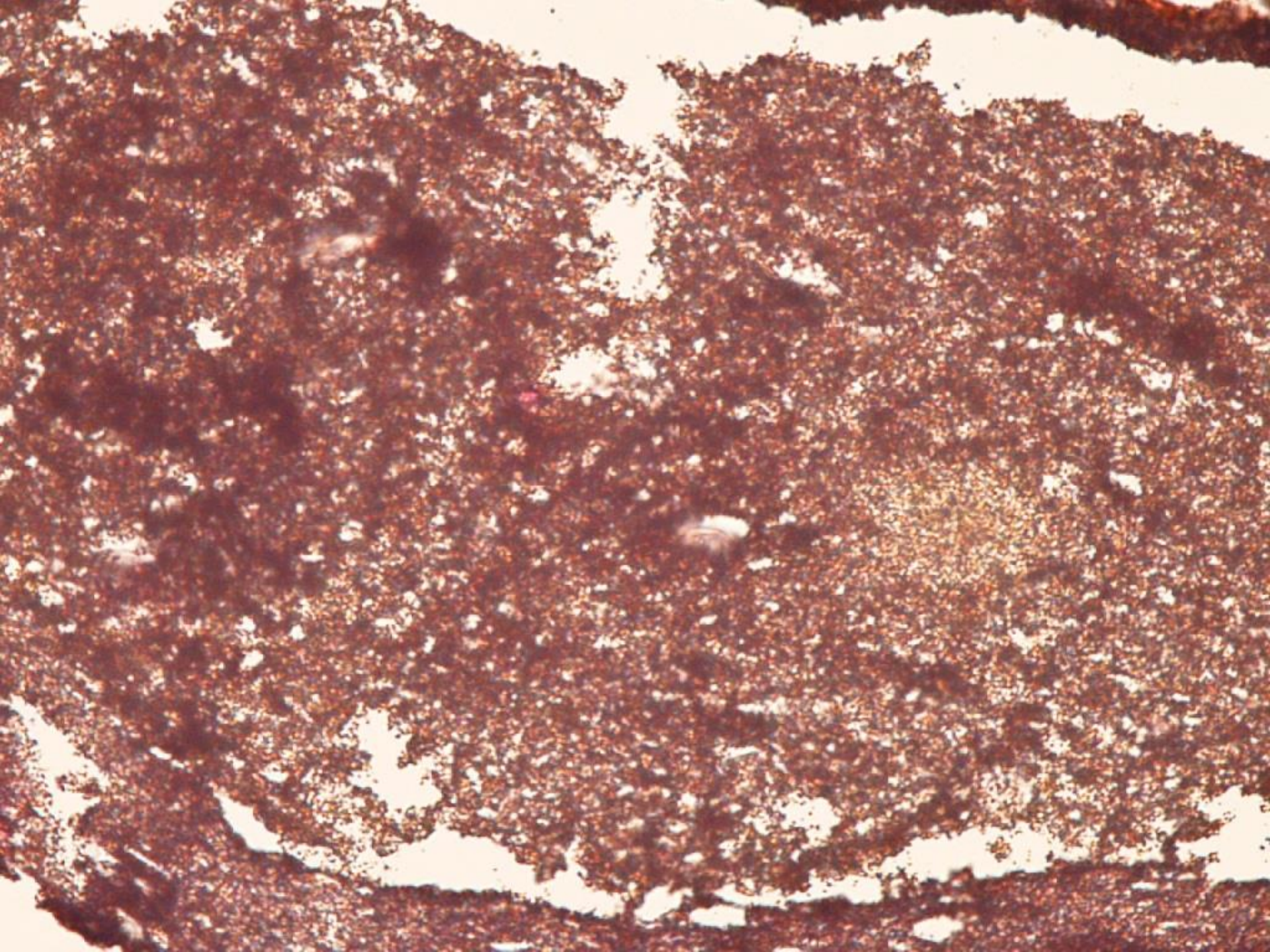
uncondensed dentin (low focus)



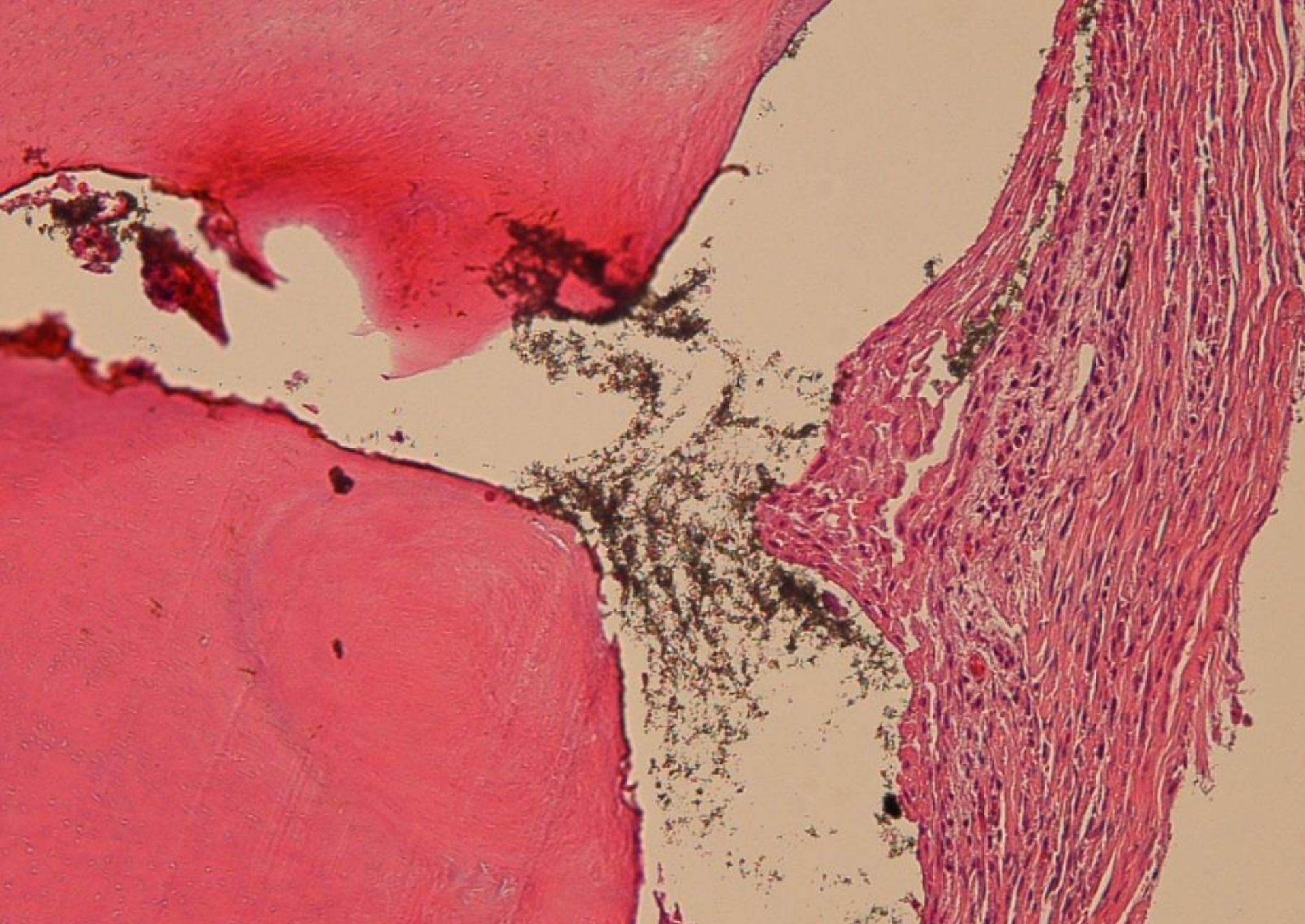


condensed dentin



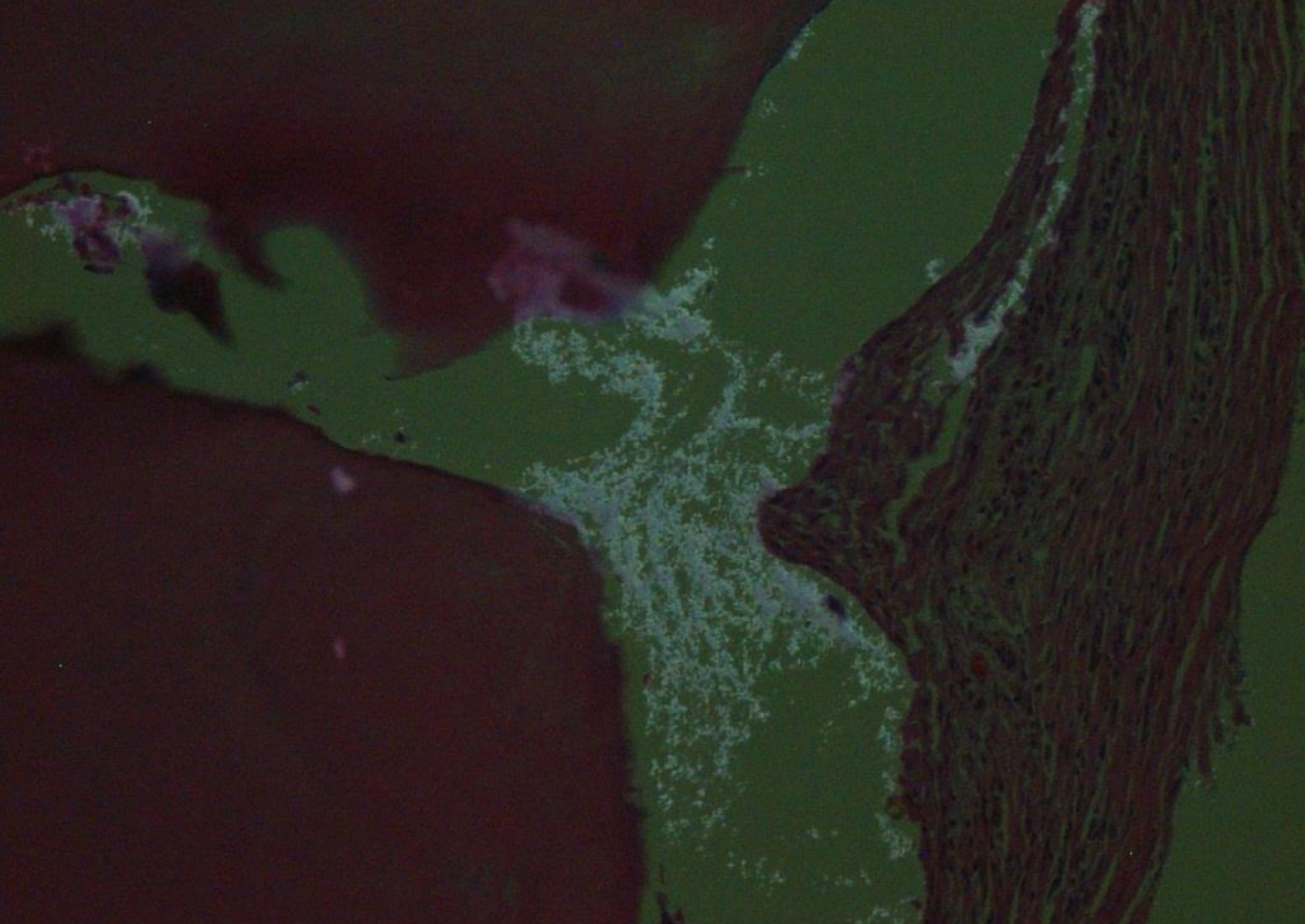






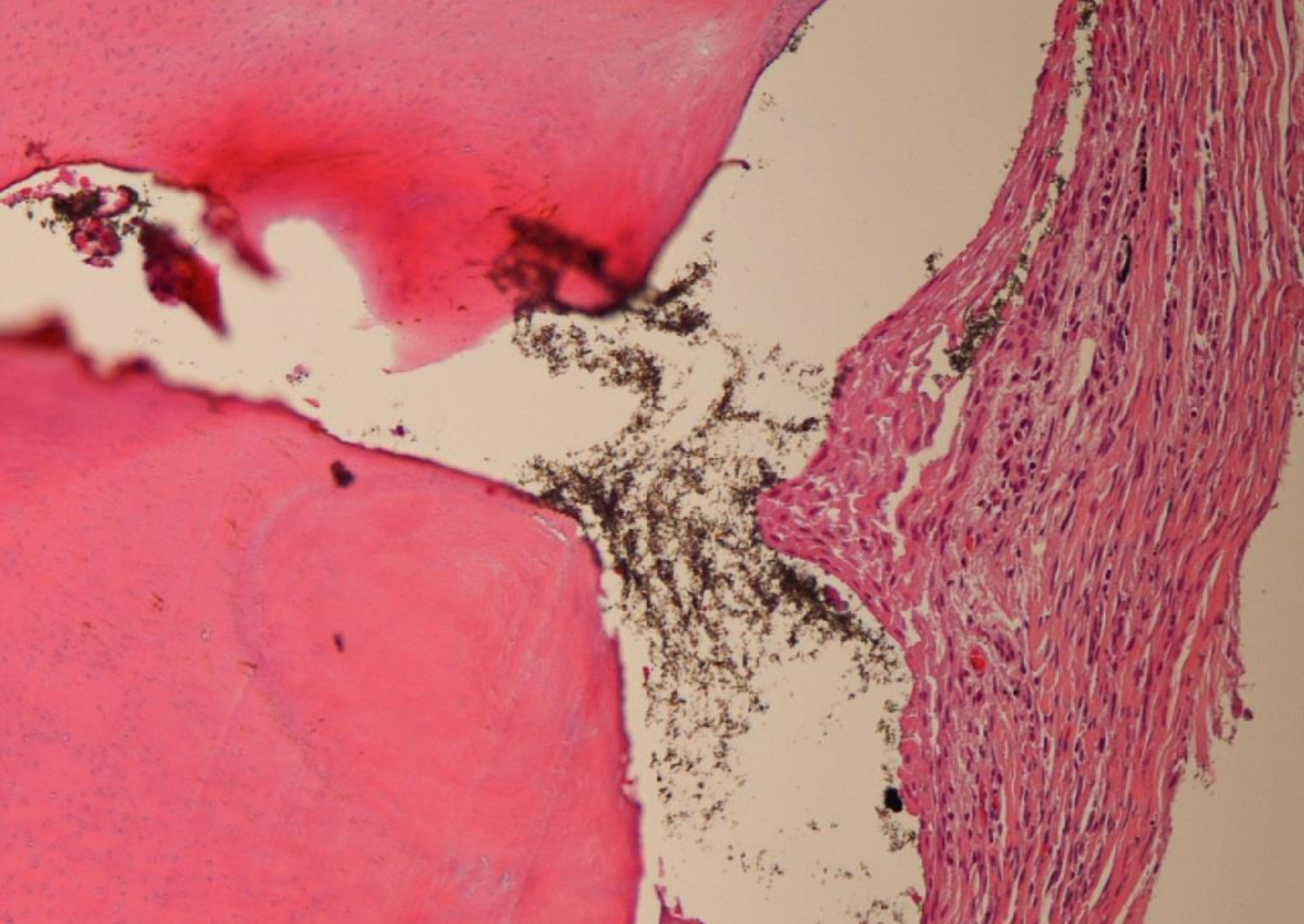
uncondensed





uncondensed, "polarized"





condensed